

นิพนธ์ต้นฉบับ

## A preliminary report of retinopathies in Thai AIDS patients.

Pakitti Tayanithi\*

Pornsawat Nantawan\* Anupot Sompopsakul\*

**Tayanithi P, Nantawan P, Sompopsakul A. A preliminary report of retinopathies in Thai AIDS patients. Chula Med J 1993 Feb; 37(2): 97-101**

*Cytomegalovirus (CMV) retinitis is the most common ocular opportunistic infection in AIDS patients. The authors present two fundus pictures that are compatible with CMV retinitis. The first case developed the fundus characteristic of CMV retinitis. The second manifested early picture of this disease.*

**Key words:** *Cytomegalovirus (CMV) retinitis, Retinopathies in AIDS.*

Reprint request : Tayanithi P, Department of Ophthalmology, Faculty of Medicine, Chulalongkorn University, Bangkok 10330, Thailand.

Received for publication. May 26, 1992.

ปภิตติ ทยานิธิ, พรสวรรค์ นันทวัน, อนุพจน์ สมภพสกุล. รายงานเบื้องต้นเรื่อง จอประสาทตาผิดปกติ  
ในผู้ป่วยไทยที่เป็นโรคภาวะภูมิคุ้มกันบกพร่อง. จุฬาลงกรณ์เวชสาร 2536 กุมภาพันธ์; 37(2): 97-101

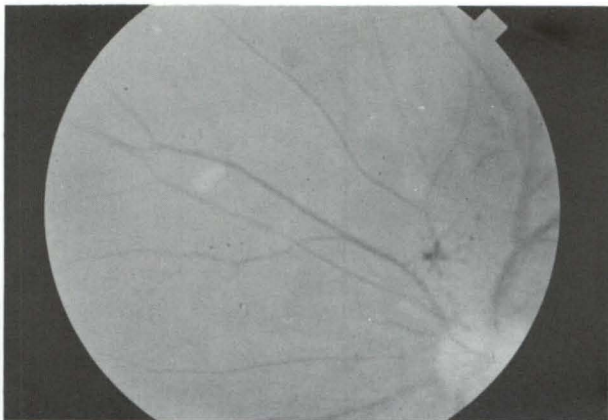จอประสาทตาอักเสบจากเชื้อ ไซโตเมกกาโลไวรัสเป็นการติดเชื้อฉวยโอกาสของตาที่พบได้บ่อยที่สุด  
ในผู้ป่วยโรคภาวะภูมิคุ้มกันบกพร่อง ผู้รายงานได้นำเสนอสิ่งตรวจพบทางจอประสาทตา ในผู้ป่วย 2 รายที่เข้าได้  
กับโรคดังกล่าว ผู้ป่วยรายที่ 1 มีลักษณะเฉพาะของโรคอย่างชัดเจน ผู้ป่วยรายที่ 2 เริ่มที่จะมีลักษณะของโรคนี้  
ในระดับต้น

AIDS was first recognized in June 1981.<sup>(1,2)</sup> The incidence of AIDS has increased dramatically since the disease was first reported. Ophthalmic manifestation occur in about 75%<sup>(3)</sup> of these patients and fall into four major categories: vasculopathies, opportunistic infections, neoplasms and neuroophthalmic abnormalities. Previous reports have suggested that retinal abnormalities are associated with severe immunoregulatory abnormalities and carry a poor prognosis.<sup>(4-6)</sup> As there is a high percentage of ocular abnormalities in these patients, ophthalmologists may initially be called on to diagnose the disease. Cytomegalovirus (CMV) retinitis is the most common ocular opportunistic infection in AIDS patients.<sup>(1,2,7-9)</sup> The authors present fundus pictures in two cases that are compatible with previously reported clinical findings in AIDS patients.

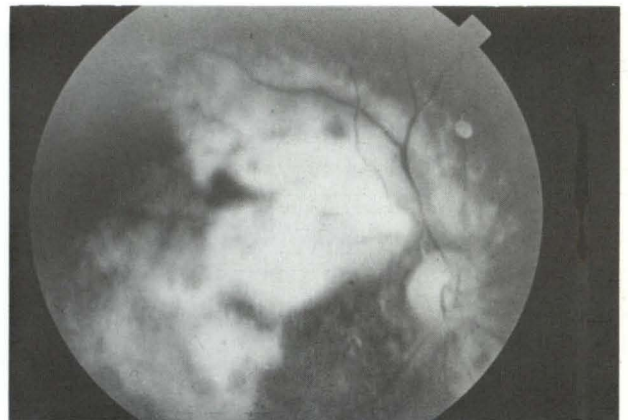
### Case 1

A 40-year-old heterosexual male was admitted in April 1989 with cough and dyspnea. He complained of weight loss (8 kg.) within two months and oral

ulcers. He had a history of tuberculous lymphadenitis and anemia one year previously and received four units of blood transfusions. He continued taking anti-TB drugs until admission. There was no history of homosexuality nor intravenous drug abuse; however, he was Anti HIV-positive. Clinical diagnosis of pneumocystis carinii pneumonia and oral candidiasis was considered. After receiving a regimen of cotrimoxazole and nystatin for 1.5 months, his condition was improved and he was discharged from the hospital. One month later, he developed a herpes simplex perianal ulcer and was treated with oral acyclovir for one month. Two months later, the patient presented with fungal septicemia and blurred vision of the right eye. Fundoscopic examination of the right eye revealed multiple intraretinal hemorrhages, retinal edema, an area of retinal necrosis exudate, and sheathing of retinal blood vessels (Figure 1). These fundus pictures were compatible with CMV retinitis. Multiple "cotton wool" spots were found in the left eyes. Two months later, characteristic CMV retinitis developed in the left eye. (Figure 2) The patient died four months later.



**Figure 1.** Fundus characteristic of CMV retinitis revealed intraretinal hemorrhage, retinal edema, necrosis and exudate. (right eye).

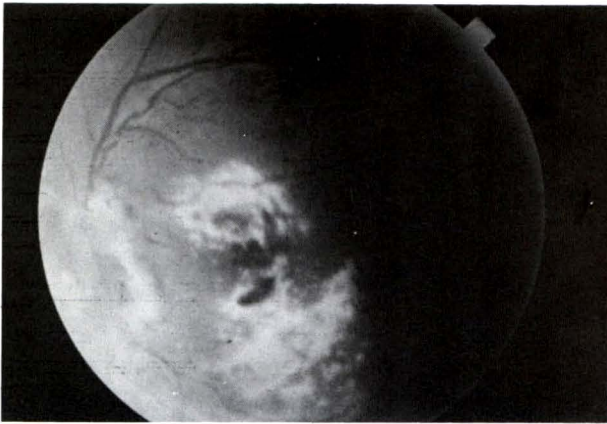


**Figure 2.** CMV retinitis in the left eye (two months later).

### Case 2

A 37-year-old bisexual male presented with prolonged fever and weight loss for one month. Anti HIV was positive. He was sent to an ophthalmologist

for eye examination. Multiple cotton wool spots were found on the right eye (Figure 3). This patients is being followed for the development of fullblown CMV retinitis.



**Figure 3.** Cotton wool spot in the right eye (second patient).

### Discussion

The manifestations of CMV retinitis are characteristic and include<sup>(1,3,4,10)</sup> one or more white and granular foci of retinal hemorrhages and exudates, retinal edema, vascular sheathing, vasculitis, Roth spots, and a slow progression by brush-fire-like expansion with retinal necrosis and destruction resembling ketchup on cottage cheese. The first case had fundus pictures as described above.

When CMV retinitis occurs, the prognosis for survival is poor. In an early report of CMV retinitis in AIDS, it was observed that few patients survived more than four months after the retinitis developed.<sup>(11,12)</sup> This was true for our first case. Subsequent studies have reported longer survival times.<sup>(5,8,13-16)</sup> The second case is being followed for the development of characteristic CMV retinitis. The earlier the diagnosis, the better medical management of concurrent illness will be. The use of the antiviral drugs ganciclovir and foscarnet have been proposed as a contributing factor. Unfortunately those antiviral drugs are not available in Thailand, we can not determine its value for treatment of our patients.

Another importance cause of visual loss in CMV retinitis in AIDS patients is retinal detachment,<sup>(8,9,17-20)</sup> which is associated with multiple small thin peripheral breaks. Healed retina after ganciclovir therapy is often atrophic and extremely thin and therefore susceptible to hole formation.

CMV retinitis is common in AIDS patient and is the major cause of visual loss. The ophthalmologist should be alerted for detecting this complication.

### References

- Schuman JS, Orellana J, Friedman AH, Teich SA. Acquired immunodeficiency syndrome. *Surv Ophthalmol* 1987 May-Jun; 31(6): 384-410
- Gold DH, Weingeist TA. *The Eye in systemic Disease*. Philadelphia: JB Lippincott, 1990. 240-3
- Freeman WR, Lerner CW, Mines JA, Lash RS, Nadel AJ, Starr MB, Tapper ML. A prospective study of the ophthalmologic finding in the acquired immune deficiency syndrome. *Am J Ophthalmol* 1984 Feb; 97(2): 133-42
- Khadem M, Kalish SB, Goldsmith J, Fetkenhour C, O'Grady RB, Phair JP, Chrobak M. Ophthalmologic finding in acquired immune deficiency syndrome (AIDS). *Arch Ophthalmol* 1984 Feb; 102(2): 201-6
- Newsome DA, Green WR, Miller ED, Kiessling LA, Morgan B, Jabs DA, Polk BF. Microvascular aspects of acquired immune deficiency syndrome retinopathy. *Am J Ophthalmol* 1984 Nov; 98(5): 590-601
- Holland GN, Sison RF, Jatulis DE, Haslop MG, Sakamoto MJ, Wheeler NC. Survival of cytomegalovirus retinopathy. *Ophthalmology* 1990 Feb; 97(2): 204-11
- American Academy of Ophthalmology. *Basic and Clinical Science Fourse*. section 3. San-Francisco; 1988-1989. 149-53
- Cross JG, Bozzette SA, Mathews WC, et al. Longitudinal study of cytomegalovirus retinitis in acquired immune deficiency syndrome. *Ophthalmology* 1990 May; 97(5): 681-6
- Sidikaro Y, Silver L, Holland GN, Kreiger AE. Rhegmatogenous retinal detachments in patients with AIDS and necrotizing retinal infections. *Ophthalmology* 1991 Feb; 98(2): 129-35
- Gal A, Pollack A, Oliver M. Ocular findings in the acquired immunodeficiency syndrome. *Br J Ophthalmol* 1984 Apr; 68(4): 238-41
- Holland GN, Pepose JS, Pettit TH, Gottlieb MS, Yee RD, Foos RY. Acquired immune deficiency syndrome, ocular manifestations. *Ophthalmology (Rochester)* 1983 Aug; 90(8): 859-73
- Palestine AG, Rodrigues MM, Macher AM, Chan CC, Lane HC, Fauci AS, Masur H, Longo D. Ophthalmic involvement in acquired immune deficiency syndrome. *Ophthalmology (Rochester)* 1984 Sep; 91(9): 1092-9
- Henderly DE, Freeman WE, Causey DM, Rao NA. Cytomegalovirus retinitis and response

- to therapy with ganciclovir. *Ophthalmology* 1987 Apr; 94(4): 425-34
14. Ussery FM<sup>3d</sup>, Gibson SR, Conklin RH, Piot DF, Stool EW, Conklin AJ. Intravitreal ganciclovir in the treatment of AIDS-associated cytomegalovirus retinitis. *Ophthalmology* 1988 May; 95(5): 649-8
  15. Jacobson MA, O' Donnell JJ, Porteous D, Brodie HR, Feigal D, Mills J. Retinal and gastrointestinal disease due to cytomegalovirus in patients with the acquired immune deficiency syndrome. Prevalence natureal history, and response to ganciclovir therapy. *QJ Med* 1988 Jun; 67(254): 473-86
  16. Jabs DA, Enger C, Bartlett JG. Cytomegalovirus retinitis and acquired immunodeficiency syndrome. *Arch Ophthamol* 1989 Jan; 107(1): 75-80
  17. Orellana J, Teich SA, Friedman AH, Lerebours F, Winterkorn J, Mildvan D. Combined short-and long-term therapy for the treatment of cytomegalovirus retinitis using ganciclovir (BW B759 U). *Ophthalmology* 1987 Jul; 94(7): 831-8
  18. Freeman WR, Handery DE, Wan WL. Causey D, Trousdale M, Green RL, Rao NA. Prevalence, pathophysiology and treatment of rhegmatogenous retinal detachment in treated cytomegalovirus retinitis. *Am J Ophthalmol* 1987 Apr 15; 103(4): 527-36
  19. Orellana J, Teich SA, Lieberman RM, Restrepo S, Peairs R. Treatment of retinal detachments in patients with the acquired immune deficiency syndrome. *Ophthalmology* 1991 Jun; 98(6): 939-43
  20. Jabs DA, Enger C, Haller J, de Bustros S. Retinal detachments in patients with cytomegalovirus retinitis. *Arch Ophthalmol* 1991 Jun; 109(6): 794-9