

Variation of branches of the subclavian artery in Thai.

Tanvaa Tansatit*

Vilai Chentanez*

Tansatit T, Chentanez V. Variation of branches of the subclavian artery in Thai. Chula Med J 1994 Apr; 38(4): 189-207

Injury to branches of the subclavian artery may arise during operations of the neck due to anatomical variation of the subclavian branches. This can be a surgical disaster with the accompanying danger or injury to more vital adjacent structures such as the brachial plexus because of the bloody field of operation. To avoid such injuries this study examined and describes the variation of the subclavian branches in 84 subjects. Numerous variations of the subclavian branches were found. The clinical significance of the observations on the subclavian branches is also discussed in this article.

Key words : *Subclavian artery.*

Reprint request : Tansatit T, Department of Anatomy, Faculty of Medicine, Chulalongkorn University, Bangkok 10330, Thailand.

Received for publication. March 30, 1994.

ธันวา ตันสภิตย์, วิไล ชินธเนศ. ความผันแปรของแขนงต่างๆ ของหลอดเลือดแดงใหญ่ใต้กระดูก
ไหปลาร้า. จุฬาลงกรณ์เวชสาร 2537 เมษายน ; 38(4): 189-207

ในระหว่างการผ่าตัดที่คือ ศัลยแพทย์อาจทำอันตรายต่อแขนงต่างๆ ของหลอดเลือดแดงใหญ่ใต้
กระดูกไหปลาร้าได้จากการที่มีความผันแปรทางกายวิภาคของแขนงหลอดเลือดเหล่านั้น สิ่งนี้อาจก่อผลให้
การผ่าตัดยากลำบากมากขึ้นและอาจพลาดไปทำความเสียหายให้กับโครงสร้างข้างเคียงที่มีความสำคัญ
อย่างมากเช่น ข่ายประสาทแขน เนื่องจากมีเลือดท่วมในบริเวณที่ทำผ่าตัด เพื่อหลีกเลี่ยงสถานการณ์นี้จึง
ได้ทำการศึกษาหาความผันแปรที่เป็นไปได้ของแขนงต่าง ๆ ของหลอดเลือดแดงใหญ่ใต้กระดูกไหปลาร้าใน
ร่างอาจารย์ใหญ่ 84 ร่าง ในการศึกษาครั้งนี้ได้รายงานความผันแปรของแขนงต่างๆ ของหลอดเลือดแดง
ใหญ่ใต้กระดูกไหปลาร้า พร้อมทั้งได้อภิปรายถึงแง่มุมทางคลินิกที่สำคัญของความผันแปรของแขนงต่าง ๆ
เหล่านี้ไว้ด้วย

Incomplete knowledge of anatomy leads to hazards in surgery of the neck and in the upper thorax. Most of the modern literature dealing with complications in head and neck surgery, and with surgical anatomy of the neck, seldom mentions the subclavian artery and its branches.⁽¹⁻¹⁷⁾ To even the experienced surgeon, inadvertent injury of the subclavian artery and its branches can be a surgical disaster.⁽¹⁸⁾ Most accounts of head and neck surgery seem to stress the importance of being gentle-handed when the operation reaches the carotid arteries and internal jugular veins. But little attention is given to the possibility of damaging other important arterial trunks which could make their weight felt in the bloody operation.⁽¹⁻¹⁷⁾ Danger or injury to these vessels may arise during separation of the malignant process adherent to the vessel wall or due to anatomical variations of the subclavian artery and its branches in the lower part of the neck.

The right subclavian artery arises from the brachiocephalic (innominate) trunk. The left subclavian artery arises typically from the arch of the aorta. They arch upward and laterally, rising usually above the level of the upper border of the clavicle, presenting themselves as a loop in the supraclavicular region. Then they pass behind the anterior scalene muscle and leave the neck by crossing the first rib, there

becoming the axillary artery.⁽¹⁹⁻²⁰⁾ The anterior scalene muscle is the landmark by which the subclavian artery is divided for descriptive purposes into three portions; the first part of each vessel is medial to the scalene, the second behind it, the third lateral to it. Except for the first part, the relation of the two subclavian arteries are similar.⁽¹⁹⁻²⁹⁾ This study specifically examined the branches of the subclavian artery and the possible anatomical variations of its origins.

Material and methods

In the course of this study, dissections were performed on 84 laboratory specimens, and for each dissection a record was made of the subclavian artery with all of its existing branches. Since much of the material was obtained as the result of medical student dissections, certain branches may have been destroyed prior to examination. In such cases the destroyed vessels were not included in the data.

A total of 168 subclavian arteries were dissected at the Department of Anatomy, Faculty of Medicine, Chulalongkorn University over a period of 3 years. In no case was there any previous surgery connected with the cervical and the upper thoracic region. After dissection some specimens were photographed.

Results (table 1 and table 2)**Table 1.** The origins of branches of the subclavian artery.

Artery	Side	Origin							
		SUBCLAVIAN A.						Other	
		Total (No)	1 st No (%)	2 nd No (%)	3 rd No (%)	Thyro- origins (see cervical table 2)		Absent	
					No (%)	No (%)	No (%)	No (%)	
Vertebral a.	L	74	74 (100)						
	R	75	74(98.67)	1 (1.33)					
	T	149	148(99.33)	1 (0.67)					
Internal thoracic a.	L	73	72(98.63)		1 (1.37)				
	R	75	72(96.00)	1 (1.33)	2 (2.67)				
	T	148	144(97.30)	1 (0.68)	3 (2.03)				
Thyrocervi- cal trunk	L	71	69(97.18)						2(2.82)
	R	74	70(94.59)					1(1.35)	3(4.05)
	T	145	139(95.86)					1(0.69)	5(3.45)
Costocervi- cal trunk	L	73	46(63.01)	25(34.25)	1(1.37)				1(1.37)
	R	75	26(34.67)	49(65.33)					
	T	148	72(48.65)	74(50.00)	1(0.68)				1(0.68)
Dorsal scapular a.	L	78	13(16.67)	9(11.54)	21(26.92)	35(44.87)			
	R	84	12(14.29)	9(10.71)	29(34.52)	31(36.90)	3(3.57)		
	T	162	25(15.43)	18(11.11)	50(30.86)	66(40.74)	3(1.85)		
Inferior thyroid a.	L	73	4(5.48)			69(94.52)			
	R	75	4(5.33)			70(93.33)	1(1.33)		
	T	148	8(5.40)			139(93.92)	1(0.68)		
Suprascapit-	L	72		1(1.39)	10(13.89)	59(81.94)	2(2.78)		
	R	74	2(2.70)		14(18.92)	56(75.68)	2(2.70)		
	T	146	2(1.37)	1(0.68)	24(16.44)	115(78.77)	4(2.74)		
Transverse cervical a.	L	73	11(15.07)	2(2.74)	3(4.11)	56(76.71)	1(1.37)		
	R	75	12(16.00)	1(1.33)	5(6.67)	57(76.00)			
	T	148	23(15.54)	3(2.03)	8(5.41)	113(76.35)	1(0.67)		

Table 2. The rare origins of branches of the subclavian artery.

(Other origins of the table 1 are described in this table).

Artery	Side	No	(%)	Origin
Thyrocervical trunk	R	1	(1.35)	Vertebral a.
Dorsal scapular a.	R	2	(2.38)	Highest intercostal a.
	R	1	(1.19)	Highest thoracic a.
Inferior thyroid a.	R	1	(1.33)	Internal thoracic a.
Suprascapular a.	R	1	(1.35)	Axillary 1st part
	L	1	(1.38)	Axillary 1st part
	L	1	(1.38)	Dorsal Scapular a.
	R	1	(1.35)	Dorsal Scapular a.
Transverse cervical a.	L	1	(1.37)	Internal thoracic a.

Table 3. The origins of the common trunks of the subclavian branches which were often found in this study.

Common trunk	side	Origin											
		SUBCLAVIAN A.						Thyro-cervical				Other	
		NO	1 st No (%)	2 nd No (%)	3 rd No (%)	No	(%)	No	(%)	No	(%)		
Dorsal scapular a. & Transverse cervical a.	L	33	9 (22.27)	1 (3.03)	3 (9.09)	20	(60.61)						
	R	33	11 (33.33)	1 (3.03)	3 (9.09)	18	(54.55)						
	T	66	20 (30.30)	2 (3.03)	6 (9.09)	38	(57.58)						
Internal thoracic a. & Thyrocervical tr.	L	7	7 (100)										
	R	2	2 (100)										
	T	9	9 (100)										
Dorsal scapular a. & Supra scapular a. & Transverse cervical a.	L	5				5	(100)						
	R	5	1 (20.00)		1 (20.00)	3	(60)						
	T	10	1 (10.00)		1 (10.00)	8	(80.00)						
Costocervical tr. & Dorsal scapular a.	L												
	R	1		1 (100)									
	T	1		1 (100)									
Suprascapular a. & Transverse cervical a.	L	1								1*	(100)		
	R	2			1 (50.00)	1	(50.00)						
	T	3			1 (33.33)	1	(33.33)	1	(33.33)	1	(33.333)		
Dorsal scapular a. & Suprascapular a.	L	1						1	(100)				
	R												
	T	1						1	(100)				

*Origin from the dorsal scapular a.

Table 4. Frequency of the subclavian branches which originated as common trunks of the subclavian branches.

Artery	Total (No)	Common trunk with	Side	No	(%)
Internal thoracic a.	148	Thyrocervical trunk	L	7	(4.73)
			R	2	(1.35)
			T	9	(6.08)
Thyrocervical trunk	145	Internal thoracic a.	L	7	(4.83)
			R	2	(1.38)
			T	9	(6.21)
Costocervical trunk	148	Dorsal scapular a.	L	0	(0.00)
			R	1	(0.68)
			T	1	(0.68)
Suprascapular a.	146	Dorsal scapular a. & Transverse cervical a.	L	5	(3.42)
			R	5	(3.42)
			T	10	(6.85)
Suprascapular a.	146	Transverse cervical a.	L	1	(0.68)
			R	2	(1.37)
			T	3	(2.05)
Suprascapular a.	146	Dorsal scapular a.	L	1	(0.68)
			R	0	(0.00)
			T	1	(0.68)
Dorsal scapula a.	162	Transverse cervical a.	L	33	(20.37)
			R	33	(20.37)
			T	66	(40.74)
Dorsal scapula a.	162	Suprascapular a. & Transverse cervical a	L	5	(3.09)
			R	5	(3.09)
			T	10	(6.17)
Dorsal scapula a.	162	Costocervical trunk	L	0	(0.00)
			R	1	(0.62)
			T	1	(0.62)
Dorsal scapula a.	162	Suprascapular a.	L	1	(0.62)
			R	0	(0.00)
			T	1	(0.62)
Transverse cervical a.	148	Dorsal scapular a.	L	33	(22.30)
			R	33	(22.30)
			T	66	(44.59)
Transverse cervical a.	148	Dorsal scapular a. & Suprascapular a.	L	5	(3.38)
			R	5	(3.38)
			T	10	(6.76)
Transverse cervical a.	148	Suprascapular a.	L	1	(0.68)
			R	2	(1.35)
			T	3	(2.03)

1. The vertebral artery

In 84 bodies, we found 149 intact vertebral arteries. All were branches of the first part of the subclavian artery except for one artery on the right side. It arose from the second part of the subclavian artery. Branches of the vertebral artery are rare in the extravertebral portion of its course. We found only one thyrocervical trunk arose from it.

2. The internal thoracic artery

Of the 148 intact internal thoracic arteries, one descended from the second part of the subclavian artery and three arteries were branches of the third part of the subclavian artery. The others were branches of the first part of the subclavian artery.

3. The thyrocervical trunk

We dissected 145 thyrocervical trunks, 139 arteries were branches of the subclavian artery medial to scalenus anterior muscle. One was a branch of the vertebral artery, and five were absent without evidence of damage.

4. The costocervical trunk

In 148 costocervical trunks (46 on the left and 26 on the right) the costocervical trunks were branches of the first part of the subclavian artery. In 25 left and 49 right, the second part of the subclavian artery gave off the costocervical trunk. Only one was found as a branch of the third part of the subclavian artery, and one was absent.

5. The dorsal scapular artery

Of the 162 dorsal scapular arteries, 25 arose from the first part of the subclavian artery. 18 were branches of the second part of the artery. In 21

on the left and 29 on the right, the dorsal scapular artery descended from the third part of the subclavian artery. In 35 on the left and 31 on the right, the thyrocervical trunk gave off this artery. In other variations found one was a branch of the highest intercostal artery and two were branches of the highest thoracic artery.

6. The inferior thyroid artery

In 148 found arteries, 139 were branches of the thyrocervical trunk. Eight arose as a single branch from the first part of the subclavian artery, and one from the right internal thoracic artery.

7. The suprascapular artery

Of 146 arteries, 115 suprascapular arteries were branches of the thyrocervical trunk. 24 arose from the third part of the subclavian artery. One on the left arose from the second part of the artery, and two on the right arose from the third part.

Four other variations, each on the right and left, arose from the first part of the axillary artery. One right and one left were branches of the dorsal scapular artery.

8. The transverse cervical artery

Of the 148 arteries, 113 arose from the thyrocervical trunk. Eight arose from the third part of the subclavian artery, three arose from the second part of this artery and 23 were given off from the third part. One internal thoracic on the left gave off the abnormal transverse cervical artery.

Common trunks of the branches of the subclavian artery are very common. They are shown in table 3 and table 4.

Discussion

The most striking anomaly of the subclavian artery frequently reported is the rather rare (about 1%) retroesophageal right subclavian artery.⁽³⁰⁻³⁶⁾ This can best be explained on the basis of the embryologic development of this segment of the vascular network.⁽³⁷⁻⁴⁰⁾ The purpose of this study was to provide more detail. We searched for variations in the branches of the subclavian artery so as to provide adequate knowledge for avoiding injury during neck operations. Of the numerous complications encountered in neck surgery, hemorrhage of the subclavian branches may cause considerable hazard.⁽¹⁸⁾

The vertebral artery

The vertebral arteries, which play such a fundamental role in anchoring the descent of the aorta, are also subject to anomalies based on variations occurring in the process of their development. It is believed that the cervical portion of the vertebral arteries is formed by a series of longitudinal anastomoses between the upper 7 dorsal segmental arteries. Usually the proximal portions of the upper 6 dorsal segmental arteries entering into this anastomosis disappear, thus leaving the vertebral artery as a branch of the subclavian artery.⁽³⁷⁻⁴⁰⁾ However, should

the proximal stem of the incorporated sixth dorsal segmental artery persist, then the right vertebral artery will take its origin from the common carotid artery, while on the left the vertebral artery will arise as a branch of the aortic arch proximal to the left subclavian artery.⁽³⁷⁻⁴¹⁾ Considering this complex embryologic development, it is surprising to learn that the vertebral arteries are the most constant of the subclavian branches. The vertebral artery is usually described as arising from the subclavian artery medial to the scalenus anterior muscle. The vessel then courses upward posteriorly to enter the foramen in the transverse process of the sixth cervical vertebra.⁽¹⁹⁻²⁹⁾ Based on our study, only one of 149 vertebral arteries arose as a branch of the second part of the subclavian artery. Branches of the vertebral artery are rare in the extravertebral portion. We found only one thyrocervical trunk originating from the right vertebral artery. A surgeon unaware of this artery might well cause serious or even fatal hemorrhage and do untold damage to such important adjacent structures as the brachial plexus, thoracic duct, common carotid artery or internal jugular vein if this vessel was accidentally torn or severed while attempting to mobilize or ligate the inferior thyroid artery as it crosses beneath the carotid sheath in doing a thyroidectomy, or attempting to excise a pharyngeal diverticulum.⁽¹⁸⁾

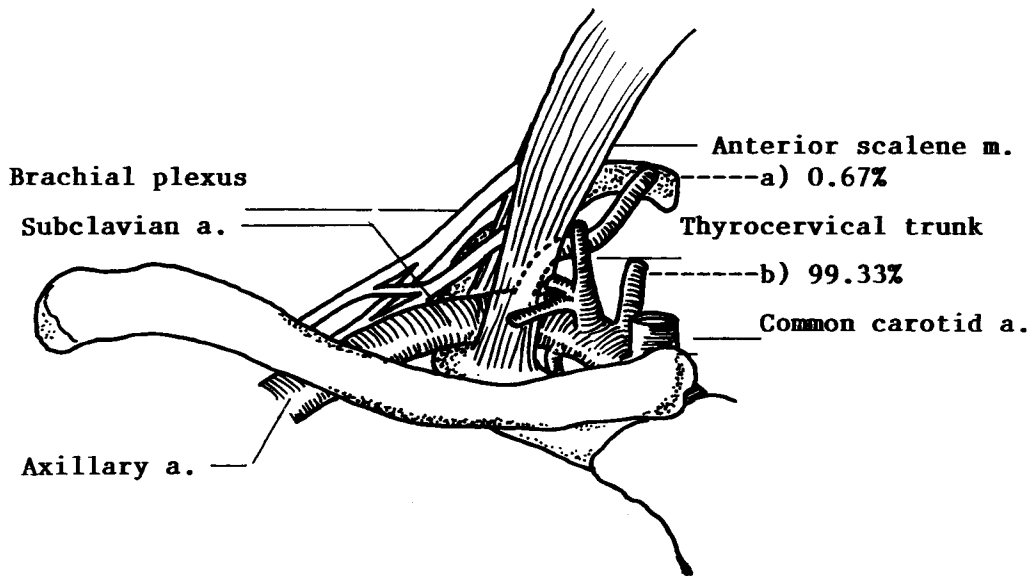


Figure 1. The sites of origin of the vertebral a.

- a) The second part of the subclavian a.(0.67%)
- b) The first part of the subclavian a. (99.33%)

The internal thoracic artery

The internal thoracic artery usually originates from the first portion of the subclavian artery, opposite the thyrocervical trunk and near the medial edge of the anterior scalene muscle.^(19-29,42-43) In the 148 arteries of our study, Four were not medial to the anterior scalene muscle. One on the right was behind this muscle and three were lateral to it. The internal

thoracic artery descends in an inward and slightly forward direction to enter the thorax behind the cartilage of the first rib. The cervical portion of the internal thoracic artery is regularly described as having no branches; however, it frequently gives rise to one or more of the thyrocervical or subclavian branches. We found one right inferior thyroid and one left transverse cervical artery arose from it.

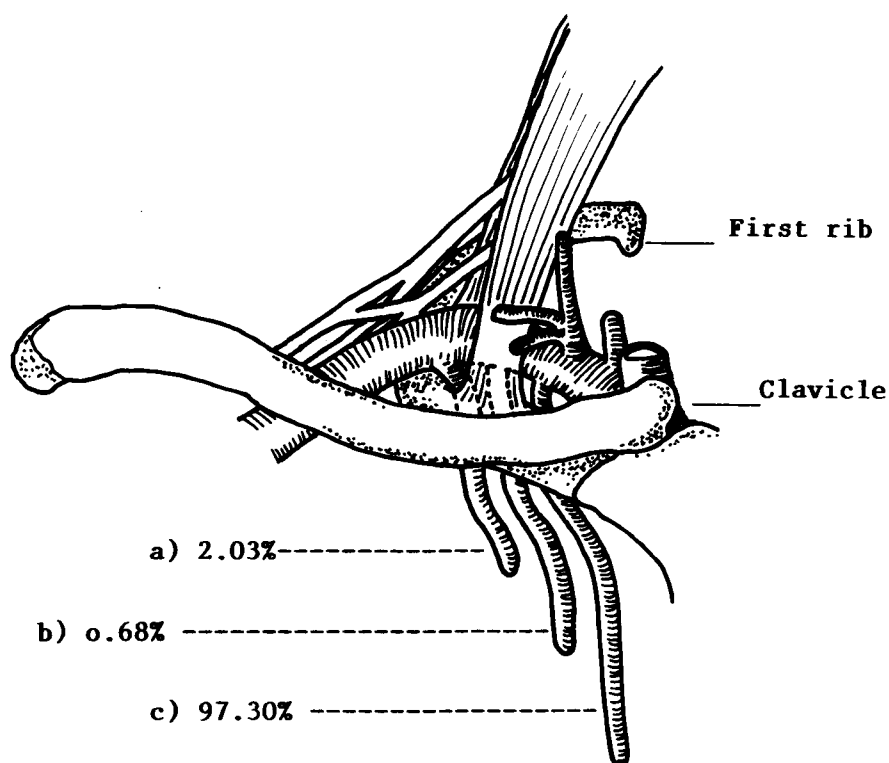


Figure 2. The sites of origin of the internal thoracic a.

- a) The third part of the subclavian a. (2.03%)
- b) The second part of the subclavian a. (0.68%)
- c) The first part of the subclavian a. (97.30%)

The thyrocervical trunk

The most variable of the major branches of the subclavian artery is the thyrocervical trunk. It can be classified on the basis of variations occurring in the derivation of branches from the thyrocervical trunk itself.⁽⁴²⁻⁴³⁾ Textbooks of anatomy usually describe the thyrocervical trunk as a short, thick trunk arising from the upper and front part of the subclavian artery opposite the origin of the internal thoracic artery and near the medial edge of the anterior scalene muscle.⁽¹⁹⁻²⁹⁾ Our examinations support this too. None of them was behind or lateral to the scalenus anterior muscle. It is said to divide almost immediately into three radiating branches; (1) the inferior thyroid artery; (2) the suprascapular artery; and (3) the transverse cervical artery.

Even though the thyrocervical trunk was absent in 3.45 percent of our cases, its constancy of location, when present, is surgically significant. When the thyrocervical trunk itself is absent, one of its major branches, usually the inferior thyroid artery, is commonly present at its usual site of origin. This vascular trunk could thus be of aid in orientation and helping to locate such surgically important structures as the lower roots and trunks of the brachial plexus, the phrenic nerve, the anterior scalenus muscle, and the thoracic duct.⁽¹⁸⁾

In addition, the thyrocervical trunk may be avulsed while exposure and division of transverse cervical artery during radical neck operations. Treatment demands immediate control of the hemorrhage by finger pressure at the site of laceration.

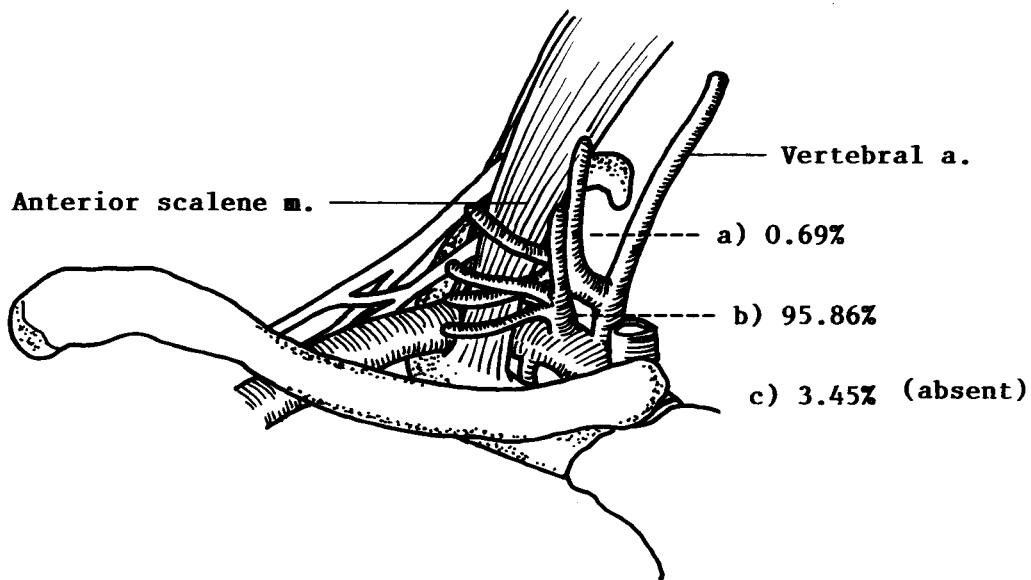


Figure 3. The sites of origin of the thyrocervical trunk.

- a) The vertebral a. (0.69%)
- b) The first part of the subclavian a. (95.86%)
- c) Absent. (3.45%)

The costocervical trunk

The costocervical trunk is a short arterial trunk which usually arises from the posterior surface of the second portion of the subclavian artery on the right side and the terminal part of the first portion of that vessel on the left side.⁽¹⁹⁻²⁹⁾ In 148 of the trunks examined, 72 were branches from the first part of the subclavian artery and 74 were branches from the second part of the artery. The subclavian artery gave off the costocervical trunk from the first part of it more on the left (L:R=46:26) and gave off this trunk from the second part of it more on the right (L:R=25:49) as it was described in the text. Just one trunk was noted on the left that originated with the third part of the subclavian artery. One was absent on the left also. After giving rise to its deep cervical arterial branch, it continues as the highest intercostal artery. The costocervical trunk and its branches, the deep

cervical trunk and the highest (superior) intercostal artery, are not of great surgical importance. These are small vessels with rich anastomotic connections and, therefore, of some importance solely as collateral channels when the vertebral, subclavian arteries and their branches require ligation or excision. The costocervical trunk and its superior intercostal branch may also be hypertrophied when coarctation of the aorta occurs. This trunk and its branches can usually be ligated with impunity.^(1-7,19-29) Their real surgical importance is due to their inaccessibility. Arising from the posterior or deep surface of the subclavian, they bifurcate almost immediately, the branches then penetrating the deep musculature and fascial structure of the neck and thorax. If torn or severed during mobilization of their subclavian source, they could cause troublesome hemorrhage, with the accompanying danger of injury to more vital adjacent structures.⁽¹⁸⁾

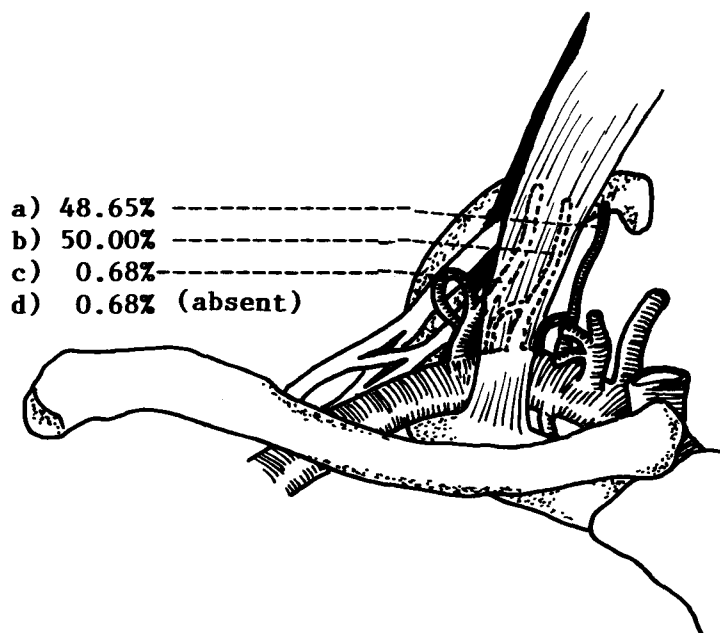


Figure 4. The sites of origin of the costocervical trunk

- a) The first part of the subclavian a. (48.65%)
- b) The second part of the subclavian a. (50.00%)
- c) The third part of the subclavian a. (0.68%)
- d) Absent (0.68%)

The dorsal scapular artery

In most of the recently published textbooks of anatomy the dorsal scapular artery, has been described as the only branch arising from the third portion of the subclavian artery or, less frequently, the second part of the subclavian artery.^(19-29,45) In our study of 162 dorsal scapular arteries, only 30 percent arose from the third part of the subclavian artery, 11 percent from the second part, 15 percent from the first part, and two percent from branches of the subclavian artery or axillary artery. The dorsal scapular artery is the principal vessel of supply to the vertebral border of scapula. The surgical importance of a dorsal scapular

artery that originates from any one of the three anatomic divisions of the subclavian artery and passes posteriorly in close relationship to brachial plexus lies in its inaccessibility and the danger of it being torn during surgical maneuvers attempting to mobilize the subclavian artery. If this vessel is torn from its site of origin in the subclavian artery, it will leave a large gaping hole in the latter vessels during removal of a cervical rib. In order to control hemorrhage, it is necessary for the surgeon to double ligate the subclavian artery on either side of the opening. If the surgeon, in seeking the distal stump of the torn vessel, had used hemostats indiscriminately in the region of the plexus, even more serious damage might occur.⁽¹⁸⁾

In addition, the dorsal scapular artery from the second or third portion of the subclavian artery may pass backward in such a manner as to ensnare the lower roots or trunk of the brachial plexus⁽⁴⁵⁾ so that they can

not possibly rise out of the narrow trough formed anteriorly by the subclavian artery, posteriorly by the scalenus medius, and inferiorly by the first rib. It is possible that such ensnaring vessels play a role in the production of the scalenus anticus syndrome.⁽¹⁸⁻⁴⁶⁾

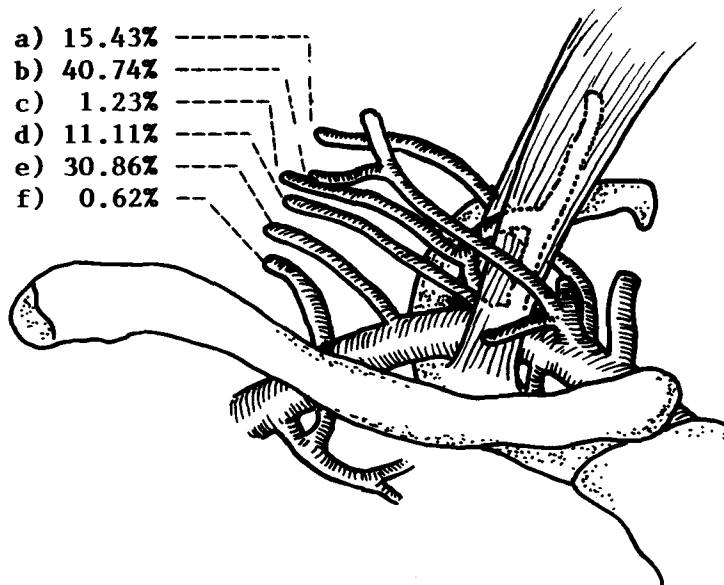


Figure 5. The sites of origin of the dorsal scapular a.

- | | |
|---|--|
| a) The first part of the subclavian a. (15.43%) | b) The thyrocervical trunk (40.74%) |
| c) The highest intercostal a. (1.23%) | d) The second part of the subclavian a. (11.11%) |
| e) The third part of the subclavian a. (30.86%) | f) The highest thoracic a. (0.62%) |

The inferior thyroid artery

Surgically speaking, the most important branch of the thyrocervical trunk is the inferior thyroid artery. Much has been written concerning the embryologic and phylogenetic development of this vessel, and its relationship to the recurrent laryngeal nerves, the parathyroid glands, the cervical sympathetic ganglia and plexus, and the vertebral arteries.^(37-40,47-48)

The inferior thyroid artery, after its origin from the thyrocervical trunk (93.92%) or directly from the subclavian artery (5.40%), ascends almost verti-

cally to the level of sixth cervical vertebra. It then turns medially and crosses behind the carotid sheath; finally it curves inferiorly before reaching the lower pole of the thyroid gland and breaking up into its terminal branches.

Although variations of the inferior thyroid artery of surgical importance are quite rare, 93.92 per cent of the vessels being derived from the thyrocervical trunk, and 5.40 per cent from the first portion of the subclavian artery and following the usual course to the gland, it behooves the careful surgeon to recall that this vessel can arise from such diverse sources as the

aortic arch, common carotid, innominate, vertebral, internal thoracic (0.68% of our study), and the more distal portion of the subclavian artery and its branches.⁽⁴²⁻⁴³⁾ It must also be remembered that when the vertebral artery has an anomalous point of entrance into the foramina of the cervical transverse processes, the inferior thyroid artery can be situated posterior to the vertebral artery. The intimate relationship of the recurrent laryngeal nerve to the inferior thyroid artery and its terminal branches is surgically so significant that surgeons who have

advocated total thyroidectomy for Graves' disease and cancer of the gland have strongly advocated routine exposure and visualization of the recurrent laryngeal nerves throughout their cervical course before excision of the gland is attempted.⁽¹⁸⁾ Some surgeons practice ligation of the inferior thyroid artery in continuity as it passes medialward beneath the carotid sheath. This practice could easily result in injury to an anomalous vertebral artery or vein, were the presence of either unrecognized.⁽⁴⁹⁾

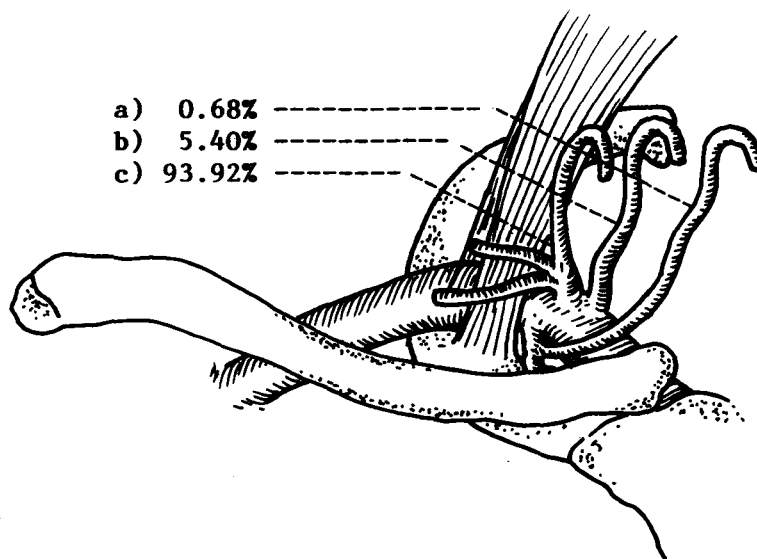


Figure 6. The sites of origin of the inferior thyroid a.

- a) The internal thoracic a. (0.68%) b) The first part of the subclavian a. (5.40%)
 c) The thyrocervical trunk (93.92%)

The suprascapular artery

The variable suprascapular artery usually arises from the thyrocervical trunk (78.77%) and, in our study, from the third part of the subclavian artery (16.44%). It curves laterally across the base of the posterior triangle of the neck, sinks beneath the posterior belly of the omohyoid muscle to reach the scapular notch. In the scapular region it establishes important anastomoses with the dorsal scapular and

circumflex scapular branch of the subscapular artery.⁽¹⁹⁻²⁹⁾

The surgical significance of this vessel, as well as that of the dorsal scapular artery, lies in its rather abundant anastomotic connections. For this reason, either vessel may be ligated with impunity because the area supplied by these vascular channels will receive adequate arterial blood from the dorsal scapular and transverse cervical arteries, from connec-

tion with each other, and from anastomoses with branches of the axillary artery (chiefly the subscapular artery).⁽¹⁹⁻²⁹⁾ These provide arterial circulation when either the second or third parts of the subclavian or the axillary arteries proximal to its subscapular branch require ligation.⁽¹⁸⁾ In cases of severe trauma which

necessitate ligation of the subclavian or axillary arteries, the thyrocervical trunk and its branches and the subscapular artery and its branches should be preserved if it is possible to do so. Collateral arterial flow through these channels may provide sufficient circulation to preserve the vitality of the involved extremity.

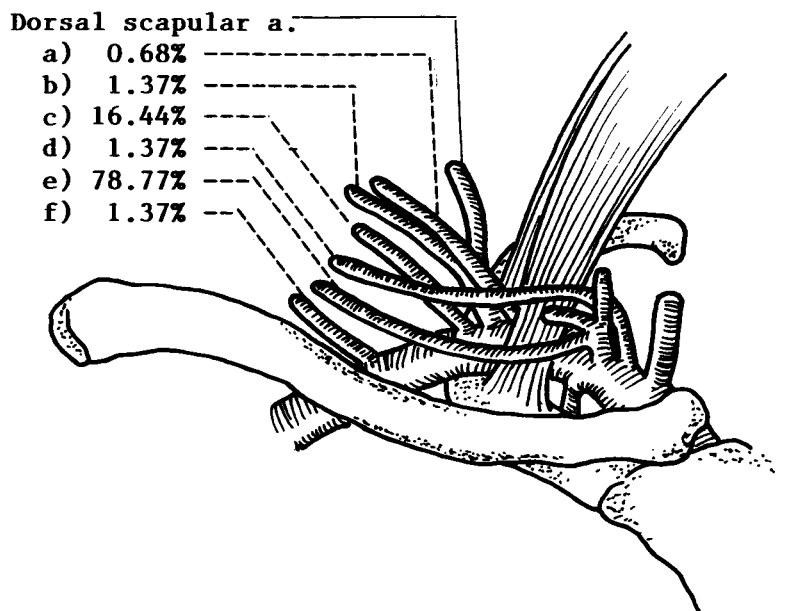


Figure 7. The sites of origin of the suprascapular a.

- a) The second part of the subclavian a. (0.68%)
- b) The dorsal scapular a. (1.37%)
- c) The third part of the subclavian a. (16.44%)
- d) The first part of the subclavian a. (1.37%)
- e) The thyrocervical trunk (78.77%)
- f) The axillary a. (1.37%)

The transverse cervical artery

The transverse cervical artery, as well as the suprascapular artery, is very variable. Of the 148 arteries, 76.35 percent arose from thyrocervical trunk, 15.54 per cent from the first part of the subclavian artery, and 7.44 per cent from the second and third part of subclavian artery. One was a branch of internal thoracic artery. It is usually described as a

moderate vessel arising from the thyrocervical trunk and coursing transversely across the neck, passing beneath the sternocleidomastoid muscle to reach the posterior triangle of the neck to reach the anterior margin of the levator scapulae. It then ascends deep to the anterior part of the trapezius muscle. It anastomoses with the descending branch of the occipital artery, dorsal scapular artery, and subscapular artery.⁽¹⁹⁻²⁹⁾

The transverse cervical artery is the major vascular supply of the trapezius. Although the trapezius muscle is less widely used than the pectoralis major muscle for muscuocutaneous flap, yet its superior location and wide anterior arc of rotation make it a valuable musculocutaneous flap. The various clinical applications of the trapezius musculocutaneous flap include (1) lower facial reconstruction,

(2) lateral upper face and scalp repair, (3) anterior and posterior neck reconstruction, (4) orbital reconstruction, and (5) pharyngoesophageal reconstruction.⁽⁵⁰⁻⁵²⁾ During these reconstruction operations, the variable vessel should be operated carefully to avoid damaging other vessels which arise from the common trunk with it, especially the dorsal scapular artery.

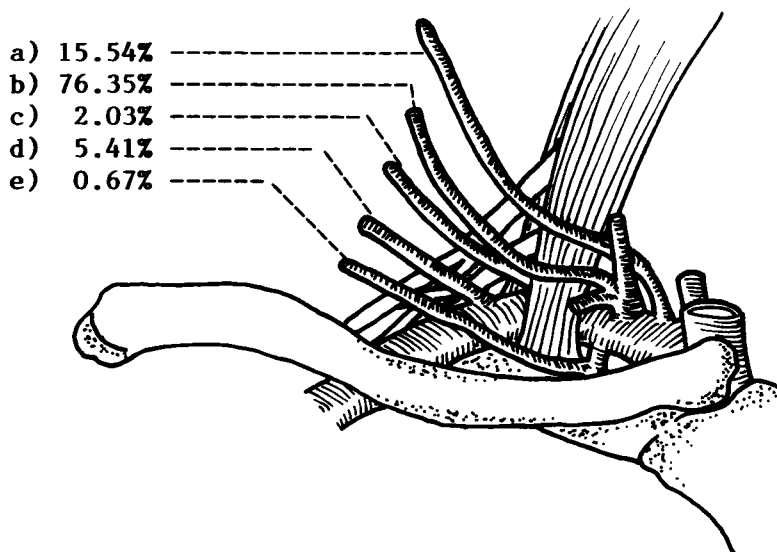


Figure 8. The sites of origin of the transverse cervical a.

- a) The first part of the subclavian a. (15.54%)
- b) The thyrocervical trunk (76.35%)
- c) The second part of the subclavian a. (2.03%)
- d) The third part of the subclavian a. (5.41%)
- e) The internal thoracic a. (0.67%)

Summary

On the basis of an anatomic study of 84 dissection specimens, the variation of the subclavian branches have been described.

The clinical significance of the observations on the subclavian branches has been discussed in those instances in which less critical knowledge of anatomy would lead to hazards during surgery of the neck and in the upper thorax.

References

1. Shah JP, ed. Color Atlas of Operative Technique in Head and Neck Surgery : Face, Skull and Neck. Ipswich : Wolfe Medical Publications, 1987.
2. Shaheen OH, ed. Problems in Head and Neck Surgery. London : Bailliers Tindall, 1984.
3. Ballantyne JC, Harrison DFN, eds. Rob & Smith's Operative Surgery : Nose and throat. 4th ed. London : Butterworths, 1986.
4. Calne SR, Pollard SG, eds. Operative Surgery. London : Gower Medical Publishing, 1992.
5. Rintouls RF, ed. Farguharson's Textbook of Operative Surgery. 7th ed. Edinburgh : Chirchill Livingstone, 1986.
6. Barclay TL, Kernahan DA, eds. Rob & Smith's Operative Surgery : Plastic Surgery. 4th ed. London : Butterworths, 1986.
7. Moylan JA, ed. Principles of Trauma Surgery. 2nd ed. New York : Gower Medical Publishing, 1992.
8. Hardy JD, ed. Hardy's Textbook of Surgery. 2nd ed. Philadelphia: J.B.Lippincott, 1988.
9. Burnett W, ed. Clinical Science for Surgeons. London : Butterworth, 1981.
10. Schrock TR, ed. Handbook of Surgery, 8th ed. Singapore : Koon Wah Printing, 1985.
11. Ellis H, Calne RY, eds. Lecture Notes on General Surgery. 6th ed. Oxford: Blackwell Scientific Publications, 1983.
12. Mann CV, Russell RCG, eds. Bailey & Love's Short Practice of Surgery. 21st ed. Hong Kong : Chapman & Hall, 1991.
13. Nyhys LM, ed. Mastery of Surgery. 1st ed. Boston : Little, Brown, 1984.
14. Schwartz SI, ed. Principles of Surgery. 5th ed. New York : McGraw-Hill, 1989.
15. Way LW, ed. Current Surgical Diagnosis & Treatment. 8th ed. Connecticut : International, 1988.
16. Taylor S, ed. Surgical Management. London : William Heinemann Medical Books, 1984.
17. Sabiston DC Jr, ed. Textbook of Surgery. 14th ed. Philadelphia : W.B.Saunders, 1991.
18. Daseler EH, Anson BJ. Surgical Anatomy of the Subclavian Artery and Its Branches. Surg Gynecol Obstet 1959 Feb;108 (2):149-74
19. Snell RS, ed. Atlas of Clinical Anatomy. 2nd ed. Boston : Little, Brown, 1978.
20. Woodburne RT, ed. Essential of Human Anatomy. 7th ed. New York : Oxford University Press, 1983.
21. Snell RS, ed. Clinical Anatomy for Medical Student. 3rd ed. Boston : Little, Brown, 1986.
22. Tortora GJ, ed. Principles of Human Anatomy. 4th ed. New York : Harper & Row, 1986.
23. Williams PL, Warwick R, Dyson M, Bannister LH. Gray's Anatomy. 37th ed. Edinburgh : Churchill Livingstone, 1989.
24. Roanmes GI, ed. Cunningham's Textbook of Anatomy. 12th ed. Oxford : Oxford University Press, 1981.
25. Rahilly RO, ed. Gardner-Gray-O'Rahilly : Anatomy : A Regional Study of Human Structure. 5th ed. Philadelphia : W.B.Saunders, 1986.

26. Ger R, Abramhams P, eds. Essentials of Clinical Anatomy. London : Pitman Publishing, 1986.
27. Lindner HH, ed. Clinical Anatomy. Connecticut : Prentice-Hall, 1989.
28. Ellis H.ed. Clinical Anatomy : A Revision and Applied Anatomy for Clinical Student. 7th ed. Oxford : Blackwell Scientific Publications, 1983.
29. Moore KL, ed. Clinical Oriented Anatomy. 3rd ed. Baltimore : Williams & Wilkins, 1992.
30. Kalke BR, Magotra R, Doshi SM. A new surgical approach to the management of symptomatic aberrant right subclavian artery. *Ann Thorac Surg* 1987 Jul;44(1) :86-9
31. Nathan H, Gitlin G. Thoracic duct terminating on the right side associated with aberrant retro-oesophageal right subclavian artery and truncus bicaroticus. *Thorax* 1968;23:226-70
32. Poon FW, Stewart IS. Aneurysm of an aberrant right subclavian artery. *Br J Radiol* 1988 Mar;61(723):249-51
33. Walker G, Geller SC. Aberrant right subclavian artery with a large diverticulum of Kommerell : a potential for misdiagnosis. *AJR* 1987 Sep;149 (3):477-8
34. Nathan H. Association of retroesophageal right subclavian arteries with thoracic duct terminating in the right venous angle. *Thorac Cardiovasc Surg* 1987 Jan;93(1):148-51
35. Proto AV, Cuthbert NW, Raider L. Aberrant right subclavian artery : Further observations. *AJR* 1987 Feb;148 (2):253-7
36. Esposito RA, Khalil I, Galloway AC, Spencer FC. Surgical treatment for aneurysm of aberrant subclavian artery based on a case report and a review of the literature. *J Thorac Cardiovasc Surg* 1988 May;95(5):888-91
37. Snell RS, ed. Clinical Embryology for Medical Students. 3rd ed. Boston; Little, Brown, 1983.
38. Sadler TW,ed. Langman's Medical Embryology. 6th ed. Baltimore:Williams & Wilkins, 1990.
39. Moore KL, ed. The Developing Human;Clinically Oriented Embryology. 3rd ed. Philadelphia : Saunders, 1982.
40. Mathews WW,ed. Atlas of Descriptive Embryology. 4th ed. New York: Macmillan, 1986.
41. Iyer AA. Some anomalies of origin of the vertebral artery. *J Anat* 1927,62:121-2
42. De Garis CF. Patterns of branching of the subclavian artery in white and negro stocks. *Am J Phys Anthropol* 1924;7:95-107
43. Bean RB. A composite study of the subclavian artery in man. *Am J Anat* 1905,4:303-28
44. Landa SJF, Lesavoy MA. Subclavian artery in head and neck surgery. *J Maxillofac. Surg* 1974 Mar;2(3):104-7
45. Huelke DF. A study of the transverse cervical and dorsal scapular arteries. *Anat Rec* 1958; 132:233
46. Adson A W. Surgical treatment for symptoms produced by cervical ribs and the scalenus anticus muscle. *Surg Gynecol Obstet* 1974 Dec (6);85:687-700

47. Reed AF. The relations of the inferior laryngeal nerve to the inferior thyroid artery. *Anat Rec.* 1943 Jan;85(1):17-23
48. Bachhuber CA. Complications of thyroid surgery : Anatomy of the recurrent laryngeal nerve, middle thyroid vein and inferior thyroid artery. *Am J Surg*,1943 Apr;60(1):96-100
49. Pemberton JDJ, Black BM. Some technical aspects of surgery of the thyroid gland. *Surg Clin N America* 1946 Aug;26(4):906-19
50. McGraw, JB, ed. *McCraw and Arnold's Atlas of muscle and musculocutaneous flaps.* Virginia : Hampton Press Publishing, 1986.
51. McCarthy JG. *Plastic Surgery.* Philadelphia : W.B. Saunders,1990
52. Millard DR Jr, ed. *Principilization of Plastic Surgery.* Boston : Little, Brown, 1986.