

Treatment of complete atrioventricular block caused by neurocardiogenic syncope with beta - adrenergic blockade therapy

Somchai Prechawat* Wichai Jirarojungkun*
Buncha Sunsaneewitayakul* Surapun Sitthisook*

Prechawat S, Jirarojungkun W, Sunsaneewitayakul B, Sitthisook S. Treatment of complete atrioventricular block caused by neurocardiogenic syncope with beta - adrenergic blockade therapy. Chula Med J 2000 Oct; 44(10): 777 - 84

Syncope can be due to a variety of abnormalities and often poses a formidable diagnostic challenge. Neurocardiogenic syncope is a common disorder of autonomic cardiovascular regulation. We report 42 year old female patient with recurrent syncope referred for further evaluation. The patient had no structural heart disease or ECG abnormality after initial assessment. The head - upright tilt testing (HUTT) was performed with the prolonged complete AV block on the surface electrocardiogram and syncope results. This response had previously been reported as a very rare phenomenon. Despite, no consensus for optimal treatment in this type of neurocardiogenic syncope, oral atenolol therapy completely prevented the recurrence of syncope and AV block induced by HUTT for the 10 months follow up period. Physicians should be aware of this type of response with neurocardiogenic syncope especially before a permanent pacemaker is considered. HUTT is an important and useful tool for assessing patients with neurocardiogenic syncope.

Key words: *Head-upright tilt testing, Complete atrioventricular block, Neurocardiogenic syncope, Atenolol, Permanent pacemaker.*

Reprint request: Prechawat S, Department of Medicine, Faculty of Medicine, Chulalongkorn University, Bangkok 10330, Thailand.

Received for publication. May 15, 2000.

สมชาย ปรีชาวัฒน์, วิชัย จิรโรจน์อังกร, บัญชา ศันสนีย์วิทย์กุล, สุรพันธ์ สิทธิสุข. การรักษา complete AV block ที่มีสาเหตุจากภาวะเป็นลมหมดสติชนิด neurocardiogenic ด้วยยาปิดกั้นเบต้า. จุลาลงกรณ์เวชสาร 2543 ต.ค; 44(10): 777 - 84

ภาวะเป็นลมหมดสติเป็นปัญหาที่พบได้บ่อยในทางเวชปฏิบัติ และเกิดได้จากหลายสาเหตุ ซึ่งจำเป็นต้องได้รับการตรวจวินิจฉัยและรักษาอย่างเหมาะสม ทั้งนี้ขึ้นกับลักษณะอาการทางคลินิกเป็นสำคัญ สาเหตุที่พบได้บ่อยคือภาวะเป็นลมหมดสติชนิด neurocardiogenic ซึ่งมักพบในผู้ป่วยที่ไม่มีโรคหัวใจผิดปกติมาก่อน เกิดจากความผิดปกติของการตอบสนองของระบบประสาทอัตโนมัติที่ควบคุมระบบไหลเวียนโลหิตในร่างกาย ในบทความนี้ได้รายงานผู้ป่วยหญิงหนึ่งรายที่มีภาวะเป็นลมหมดสติชนิด neurocardiogenic ซึ่งยืนยันการวินิจฉัยด้วยการตรวจ head – upright tilt testing (HUTT) แต่มีผลการตอบสนองจากการตรวจโดยพบเป็น complete AV block ซึ่งถือว่าการตอบสนองที่พบได้น้อยมาก และการรักษาผู้ป่วยในลักษณะเช่นนี้ยังไม่ทราบว่าวิธีใดจะดีที่สุดในปัจจุบัน อย่างไรก็ตามหลังการรักษาด้วยยา atenolol พบว่าได้ผลการรักษาที่ดีที่สุดสามารถป้องกันการเกิดซ้ำของภาวะเป็นลมหมดสติได้ และยังทำให้การตรวจ HUTT ซ้ำ มีผลเป็นลบอีกด้วย

ดังนั้นจากรายงานนี้จึงพบว่ายาปิดกั้นเบต้า ซึ่งถือว่าโดยทั่วไปเป็นยาที่ห้ามใช้ในผู้ป่วย complete AV block แต่ในกรณีที่เกิดจากภาวะเป็นลมหมดสติชนิด neurocardiogenic ก็พบว่ายายังคงมีประสิทธิภาพในการรักษาได้ ฉะนั้นแพทย์ผู้ตรวจพบปัญหา complete AV block ในผู้ป่วยที่มีอาการทางคลินิกซึ่งอาจเกิดจากภาวะเป็นลมหมดสติชนิดนี้ จึงควรสั่งทำ HUTT ก่อนพิจารณาใส่เครื่องกระตุ้นไฟฟ้าชนิดถาวรให้กับผู้ป่วย

Syncope is defined as a sudden transient loss of consciousness secondary to inadequate blood flow to the brain and is often associated with a loss of postural tone with spontaneous recovery, usually over a brief period of time.⁽¹⁾ Syncope is a relative common occurrence in the general population accounting for 1 to 6 % of hospital admissions and 3% of emergency room visits each year.⁽²⁾ It has a variety of causes, and it is often necessary to use a variety of diagnostic modalities in order to obtain an accurate diagnosis. One form of syncope that is reported to account for more than 50 % of cases is neurocardiogenic (vasodepressor syncope), and can generally be diagnosed with head - upright tilttesting (HUTT). Three types of positive HUTT have been observed during the tests. These are vasodepressor, cardioinhibitory, and mixed type. With mixed type, loss of consciousness occurs with a sudden and prolonged decrease in blood pressure and heart rate. Vasodepressor type occurs with a decrease in blood pressure but not heart rate. Cardioinhibitory type occurs with predominant bradycardia. We described a patient who had been diagnosed with neurocardiogenic syncope, and had HUTT response with prolonged complete AV block. Complete AV block induced by HUTT is a very rare phenomenon,⁽³⁾ and permanent pacemaker therapy is still controversial.^(4,5) The beta blockers, in general, are contraindicated for complete AV block. However, in cases of neurocardiogenic syncope they are thought to act by decreasing ventricular C-fiber stimulation and blunting the pathophysiologic effects of the initial catecholamine surge that plays an important role in precipitating the syncope. We present a case in which oral beta blocker therapy prevented the recurrence of syncopal

episode associated with prolonged complete AV block induced by head – upright tilt testing.

Case Report

A 42 year old woman was referred for investigation of recurrent episodes of syncope. Some episodes were preceded by a prodrome of dizziness, however, other episodes occurred quite abruptly. On physical examination, no abnormalities were noted. The 12 - lead electrocardiogram was normal, and 24 hour Holter monitoring was also non diagnostic at the time of referral. Echocardiography was performed and was normal. The cause of her syncope was assessed as not being due to heart disease. Her syncopal episodes likely represented neurocardiogenic syncope. HUTT was performed using an electrically controlled tilt table with a foot board for weight bearing. The electrocardiogram was monitored continuously. Blood pressure was monitored once a minute using a cuff tube automatic blood pressure instrument. On baseline HUTT her blood pressure was 130/70 mmHg and the heart rate was 60 beats/min. She could tolerate 30 minutes of tilt at an 80 degree tilt angle without significant hemodynamic changes. She then received 400 micrograms of sublingual spray of nitroglycerine and was retilted at an 80 degree tilt angle. Four minutes after the second test had been started, as shown in Figure 1, her blood pressure had fallen to 40/20 mmHg and the electrocardiogram showed prolonged complete AV block for more than 15 seconds without junctional or ventricular escape rhythms (Figure 2) and syncopal episode occurred abruptly. After she was returned to the supine position for 1 minute her BP was 150/70 mmHg and the heart rate was 68 beats/min without

any complication. She was diagnosed with neurocardiogenic syncope and oral atenolol therapy (50 mg/day) was initiated for two weeks. The HUTT was repeated with the same protocol at the same time of day as the initial study. No hypotension, bradycardia and/or syncope occurred during the test with or without the use of sublingual nitroglycerine. She was symptom-free during 10 months follow up.

Discussion

The diagnosis of unknown syncope is best guided by clinical features. Syncope must be differentiated from other states of altered consciousness such as seizure, coma, drop attacks and metabolic disturbances (e.g. hypoglycemia). Treadmill testing and EEG are not likely to be diagnostic unless the clinical history supports their

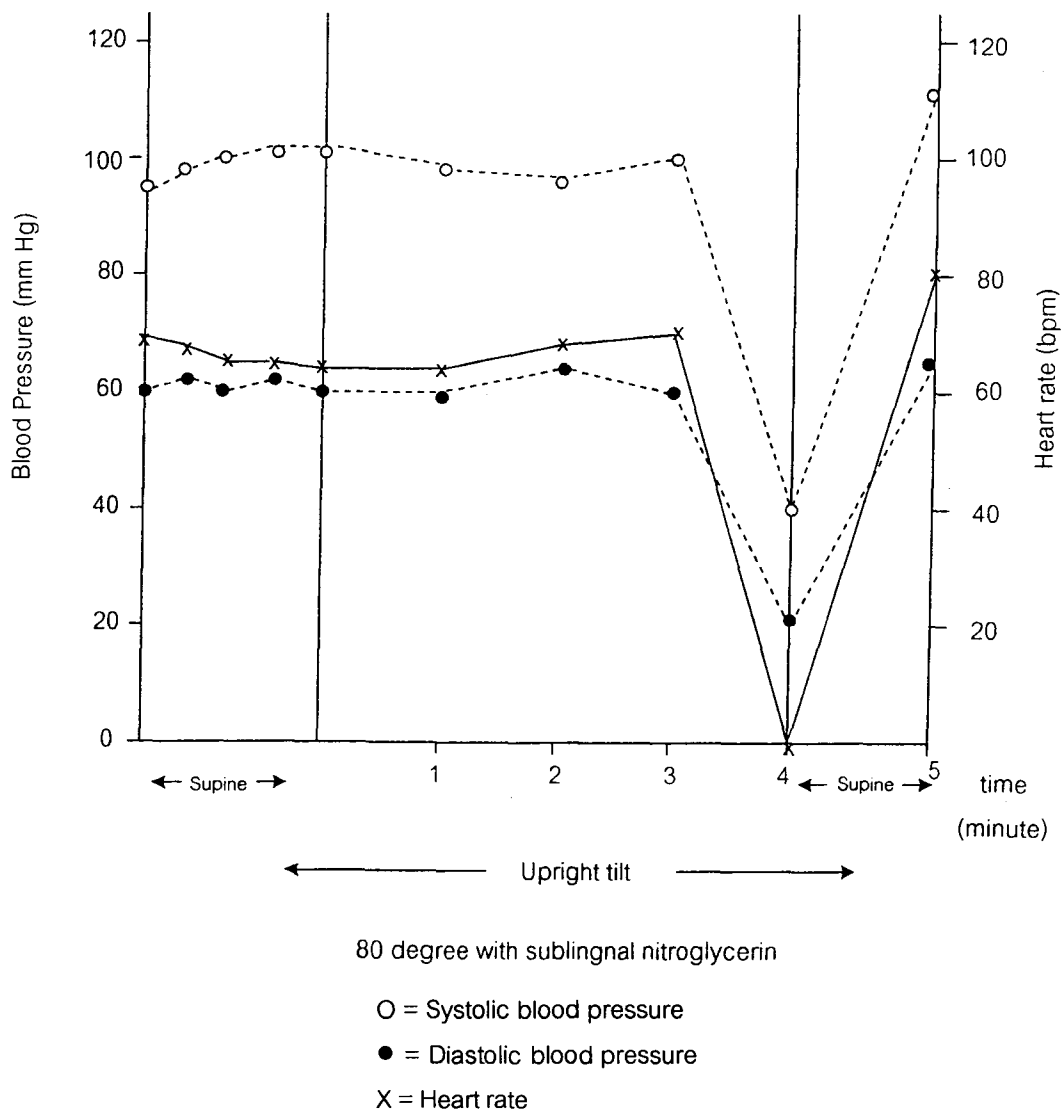


Figure 1. Hemodynamic parameters during head-upright tilt testing are demonstrated. Bradycardia and hypotension occurred abruptly with syncope at 4 minutes after HUTT at 80 degree with sublingual nitroglycerin. Open circle, closed circle, and X show systolic blood pressure, diastolic blood pressure, and heart rate, respectively.

use. The 24-hour Holter monitoring is rarely diagnostic unless the episodes of syncope are very frequent. Electrophysiologic testing is not likely to give a diagnosis in patients free of structural or electrical heart disease.⁽⁷⁾ Neurocardiogenic (also known as vasovagal, neurally mediated or vasodepressor syncope) is the most common cause of syncope in previously healthy persons.⁽⁸⁾ The pathophysiological mechanisms of neurocardiogenic syncope are : 1) The central type; This pathway descends from cortico-hypothalamic centers to the medullary cardiovascular center. In susceptible human subjects with severe emotional stress and severe pain, it may lead to syncope. The bradycardia and hypotension are usually

preceded by moderate tachycardia and hypertension. Recently, several studies have focused on the central mechanisms that contribute to the production of neurocardiogenic syncope. Endogenous opioids and serotonin have been identified as participants in the vasodepressor response⁽⁹⁾ 2) The peripheral type : This pathway originates in the heart itself via a mechanism known as the Bezold-Jarisch reflex. The combination of an increased inotropic stimulus to the heart and a decreased volume in the left ventricle is thought to give rise to a powerful contraction around an empty heart chamber, leading to activation of ventricular mechanoreceptors or nonmyelinated C-fibers. These afferent C-fibers project centrally to the

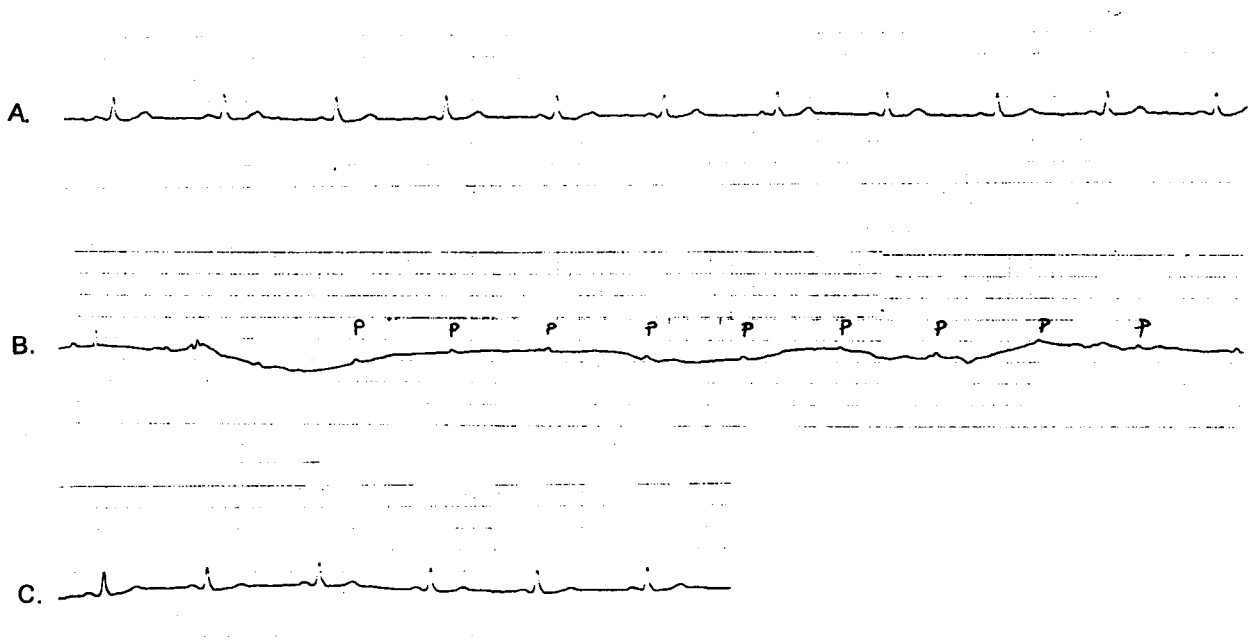


Figure 2. (A) ECG tracing (lead II) before syncope, monitored during HUTT without sublingual nitroglycerin
(B) ECG tracing during syncope induced by HUTT with sublingual nitroglycerin, the complete AV block occurred abruptly without junctional or ventricular escape rhythms. The duration of complete AV block was more than 10 seconds.
(C) ECG tracing after syncopal attack in supine position. The normal sinus rhythm was shown with normal PR interval (0.18 second)

dorsal vagal nucleus of the in brain stem. Stimulation of these fibers leads to "paradoxical" inhibition of efferent sympathetic tones (vasodilation and hypotension), enhancement of parasympathetic activity (bradycardia) and syncope. HUTT reduces venous return, and this led to : 1) Slight reduction in systolic blood pressure with subsequent increase in serum catecholamines, and 2) a small left ventricle cavity. Vigorous contraction of a small ventricle initiates the reflex cascade for neurocardiogenic syncope. This results in hypotension and/or bradycardia with syncope. Thus the most useful test for evaluation of unexplained syncope in patients without structural heart disease has been HUTT. The protocols are variable, but in an attempt to standardize them an expert panel convened by the American College of Cardiology recently published recommendations which may be summarized as follows.⁽¹⁰⁾ The patient should be tested in a fasting state while receiving intravenous fluid replacement in a dim, quiet room with a comfortable temperature. All essential drugs should be withheld for several half-lives before the procedure. The blood pressure and electrocardiogram should be monitored continuously. The table should have a foot board support with capability for rapid and smooth transitions between various angles. A passive tilt angle of 70 to 80 degrees for a duration of 30 to 45 minutes should be used if needed with pharmacologic provocation with low dose isoproterenol infusion begun. Beginning in the supine position followed by 10 to 15 minutes of HUTT is preferred. A trained cardiovascular nurse or technician should be present during the entire procedure, with the supervising physician either in attendance or in close proximity. The sensitivity of HUTT has been

reported to range from 32 to 85 % and it can be increased by using longer tilt durations, steeper tilt angles, and provocative agents such as isoproterenol and nitroglycerin. In the absence of pharmacologic provocation, the specificity of the test has been estimated to be 90 %.⁽¹¹⁾ Recent data has shown that sublingual nitroglycerin could be used for provocative agent. Nitroglycerin seems to provide a better sensitivity, specificity and is safer than isoproterenol.⁽¹²⁻¹⁴⁾ For these reasons sublingual nitroglycerin was chosen on our patient. There are three types of positive HUTT responses: vasodepressor, cardioinhibitory and mixed type. In most of the reported cases of cardioinhibitory and/or mixed type, it was been shown that the bradycardia recorded on the electrocardiogram was sinus bradycardia or sinus arrest.⁽¹⁵⁾ Occasionally, asystole lasting for several seconds has been implicated in the so called malignant vasovagal syndrome. Although vagally mediated reflexes exert an effect on the SA and AV nodes, high grade or complete AV block is uncommon because the vagal effect on the sinus node usually predominates, thus masking the effect of vagal stimulation on the AV node.⁽¹⁶⁾ For this reason, advanced or prolonged complete AV block associated with neurocardiogenic syncope is thought to be a very rare phenomenon. For treatment of neurocardiogenic syncope, pharmacologic therapy usually is used for those in whom syncope is recurrent or has been associated with physical injury or potential occupational hazards. Several strategies have been proposed on the basis of data from uncontrolled studies. The drugs most widely used are beta blockers.⁽¹⁷⁾ These agents presumably exert their effect by diminishing the degree of cardiac

mechanoreceptor stimulation and by blocking the high levels of catecholamines. However, in general beta blockers are contraindicated in patients who had complete AV block. Permanent pacemaker therapy is indicated in such patients. In patients with neurocardiogenic syncope, especially cardioinhibitory type permanent pacemaker therapy is still controversial.^(5,6,18) On the other hand, there are many reports which have shown that beta blocker treatment guided by HUTT is effective in treating patients with malignant vasovagal syndrome.^(4,5,17,19) Conservative management, with nonpharmacological⁽²⁰⁾ and pharmacological therapy, is recommended for the initial method before considering the permanent pacemaker therapy. The permanent pacemaker should be considered after failed conservative treatment. The patient in case, who exhibited a prolonged complete AV block with syncope induced by HUTT, was treated successfully with oral atenolol therapy. Thus, syncope caused by complete AV block may include neurocardiogenic syncope. Beta blockers may be useful therapy for prevention of syncope caused by complete AV block in neurocardiogenic syncope. HUTT is a useful and important diagnostic tool, particularly before permanent therapy is considered.

References

1. Kapoor WN. Work up and management of patients with syncope. *Med Clin North Am* 1995 Sep; 79(5): 1153 - 70
2. Day SC, Cook EF, Funkenstein H, Goldman L. Evaluation and outcome of emergency room patients with transient loss of consciousness. *Am J Med* 1982 Jul; 73(1): 15 - 23
3. Sumiyoshi M, Nakata Y, Mineda Y. Paroxysmal atrioventricular block induced head-up tilt testing in an apparently healthy man. *J Cardiovasc Electrophysiol* 1997 May; 8(5): 561 - 4
4. Pentousis D, Cooper JP, Cobbe SM. Prolonged asystole induced by head up tilt test. Report of four cases and brief review of the prognostic significance and medical management. *Heart* 1997 Mar; 77(3): 273 - 5
5. Petersen ME, Chamberlain-Webber R, Fitzpatrick AD, Ingram A, Williams T, Sutton R. Permanent pacing for cardioinhibitory malignant vasovagal syndrome. *Br Heart J* 1994 Mar; 71(3): 274 - 81
6. Connolly SJ, Sheldon R, Roberts RS, Gent M. On behalf of the Vasovagal Pacemaker Study Investigators: The North American Vasovagal Pacemaker Study (VPS). A randomized trial of permanent cardiac pacing for the prevention of vasovagal syncope. *J Am Coll Cardiol* 1999 Jan; 33(1): 16 - 20
7. Klein GJ, Lerman BB, Tavel ME. Syncope: common clinical problem of diagnosis and management. *Chest* 1994 Apr; 105(4): 1246 - 8
8. Henderson MC, Prabhu SD. Syncope: current diagnosis and treatment. *Curr Probl Cardiol* 1997 May; 22(5): 243 - 96
9. Rea RF, Thames MD. Neural control mechanisms and vasovagal syncope. *J Cardiovasc Electrophysiol* 1993 Oct; 4(5): 587 - 95
10. Benditt DG, Ferguson DW, Grubb BP, Kapoor WN, Kugler J, Lerman BB, Maloney JD, Raviele A. Tilt table testing for assessing syncope. *J Am Coll Cardiol* 1996 Jul; 28(11): 263 - 75
11. Grubb BP, Kosinski D. Tilt table testing: concept

- and limitations. *Pac Clin Electrophysiol* 1997 Mar; 20(3 pt 2): 781 - 7
12. Del Rosso A, Bartoli P, Bartoletti A., Brandinelli – Geri A, Bonechi F, Maioli M, Mazza F. Shortened head-up tilt testing potentiated with sublingual nitroglycerin in patients with unexplained syncope. *Am Heart J* 1998 Apr; 135(4): 564 - 70
13. Natale A, Sra J, Akhtar M, Pacifico A, Kusmirek L, Tomassoni G, Leonelli F, Newby K. Use of sublingual nitroglycerin during head-up tilt - table testing in patients > 60 years of age. *Am J Cardiol* 1998 Nov 15; 82(10): 1210 - 3
14. Manzillo GP, Giada F, Raviele A. Reproducibility of head - up tilt testing potentiated with sublingual nitroglycerin in patient with unexplained syncope. *Am J Cardiol* 1999 Aug; 84(3): 284 - 8
15. Dhala A, Nalale A, Sra J, Deshpande S, Blanck Z, Jazayeri MR, Akhtar M. Relevance of asystole during head-up tilt testing. *Am J Cardiol* 1995 Feb 1; 75(4): 251 - 4
16. Strasberg B, Lam W, Swiryn S, Bauernfeind R, Scagliotti O, Palileo E, Rosen K. Symptomatic spontaneous paroxysmal AV nodal block due to localized hyperresponsiveness of the AV node to vagotonic reflexes. *Am Heart J* 1982 May; 103 (5): 795 - 801
17. Atiga WL, Rowe P, Calkins H. Management of vasovagal syncope. *J Cardiovasc Electrophysiol* 1999 Jun; 10(6): 874 - 86
18. Gregoratos G, Cheitlin MD, Corill A, Epstein AE, Fellows C, Ferguson TB Jr, Freedman RA, Hlatky MA. ACC/AHA guidelines for implantation of cardiac pacemakers and antiarrhythmia devices. Executive Summary. A report of the American College of Cardiology/ American Heart Association Task Force on Practice Guidelines (Committee on Pacemaker Implantation). *Circulation* 1998 Apr; 97(13): 1325-35
19. Biffi M, Doriani G, Sabbatani P, Bronzetti G, Frabetti L, Zamsoli R, Branzic A, Magnani B. Malignant vasovagal syncope : a randomized trial of metoprolol and clonidine. *Heart* 1997 Mar; 77(3): 268 - 72
20. Ector H, Reybrouck T, Heidbuchel H, Gewillig M, Van de Werf F. Tilt training : a new treatment for recurrent neurocardiogenic syncope and severe orthostatic intolerance. *Pacing Clin Electrophysiol* 1998 Jan ; 21(1 pt 2): 193 - 6