

Adjacent interdigital pinning: a pilot study of a novel technique for periarticular base fracture of proximal phalanx

Nattawut Sastravaha*

Worasun Taweewuthisub* Soarawit Weerasopone*

Sastravaha N, Taweewuthisub W, Weerasopone S. Adjacent interdigital pinning: a pilot study of a novel technique for periarticular base fracture of proximal phalanx. Chula Med J 2018 Jul – Aug; 62(4): 675 - 86

Background : *Fractures of the phalanx account for more than 20% of all upper extremities fracture, mostly, proximal phalanx (P1) fracture. Managing periarticular fracture of P1 has remained a challenging problem for hand surgeon especially comminuted fracture. Several operative techniques were performed to gain anatomical reduction, stable fixation and early range of motion. We proposed a novel technique: adjacent interdigital pinning.*

Objective : *The aims of this study were determined the outcome of periarticular base of P1 fractures performed by the surgical procedure, namely: adjacent interdigital pinning technique.*

Methods : *A periarticular base of P1 fracture was reduced by distal traction. The early joint exercise was allowed because both metacarpophalangeal (MCP) and proximal interphalangeal (PIP) remained free of motion. The two or three pins were inserted into the proximal phalanx of injured digit to the proximal phalanx of nearby digit after the fracture was reduced. Fluoroscopy was used to check alignment and reduction. Range of motion (ROM) exercise started immediately after the operation.*

Results : *Three patients with periarticular P1 fractures were recruited. The average follow-up period was 3 months. The mean ROM of the injured MCP of those 3 patients was 83°. The mean ROM of PIP was 80°. The patients reported visual analogue pain score of 0 - 1 after 3 months of operation. The grip strength was at least 80% compared to uninjured side. All cases were union within 4 weeks without serious complication. The angulation of fracture sites were not more than 10 degree in coronal and sagittal view.*

Conclusion : *Adjacent interdigital pinning is economical, easy for application and provides good results; thus, it should be an alternative way to manage periarticular P1 fracture.*

Keywords : *Adjacent interdigital pinning, periarticular proximal phalanx fracture.*

Correspondence to : Weerasopone S. Department of Orthopedic, Queen Savang Vadhana Memorial Hospital, Chonburi, Thailand.

E-mail: poptient@gmail.com

Received for publication. January 19, 2018.

ณัฐวุธ ศาสตราวหา, วรสันต์ ทวีวุฒิทรัพย์, สรวิศร์ วีระโสภณ. การผ่าตัดกระดูกนิ้วมือส่วนต้นชนิดแตกย่อย วิธียึดฝากนิ้วข้างเคียง: การศึกษานำร่อง. จุฬาลงกรณ์เวชสาร 2561 ก.ค. - ส.ค.;62(4): 675 - 86

- เหตุผลของการทำวิจัย** : กระดูกหักบริเวณนิ้วมือพบได้มากถึงร้อยละ 20 ของกระดูกระยะขาค์ส่วนบน มีจำนวนไม่น้อยที่มีการหักบริเวณกระดูกนิ้วมือส่วนต้น (proximal phalanx) ยังไม่มีการผ่าตัดที่เป็นมาตรฐานโดยเฉพาะตำแหน่งหักเข้าข้อ (periarticular part) การรักษาควรประกอบด้วยกายวิภาคของกระดูกที่ใกล้เคียงเดิม (anatomic reduction) อุปรกรณ์ตรึงยึดที่แข็งแรง (stable fixation) และการเริ่มกายภาพทันที (early range of motion)
- วัตถุประสงค์** : ประเมินผลการรักษาด้วยวิธีการยึดฝากนิ้วเคียง (interdigital dynamic fixator technique) ในกระดูกหักของนิ้วมือส่วนต้นชนิดแตกย่อย (comminuted periarticular base of proximal phalanx fracture)
- วิธีการทำวิจัย** : เริ่มจากการดึงกระดูกให้เข้าที่ (distal traction) ใช้ลวดผ่าตัดตรึงกระดูก 2 - 3 ชิ้น เชื่อมผ่านนิ้วข้างเคียงหลังจากที่กระดูกหักได้ถูกดึงให้กลับที่แล้ว ตรวจแนวกระดูกด้วย fluoroscope ทดสอบการขยับของข้อต่อ metacarpophalangeal joint (MCP) และ proximal interphalangeal joint (PIP) หลังจากผ่าตัด ให้เริ่มการทำกายภาพทันที
- ผลการศึกษา** : ผู้ป่วย 3 รายได้ทำการผ่าตัดวิธีนี้ นัดติดตามอย่างน้อย 3 เดือน ผลการรักษา ในกลุ่มผู้ป่วยนี้ ค่าเฉลี่ยของ ROM ของ MCP คือ 83 องศา ค่าเฉลี่ยของ PIP คือ 80 องศา ตรวจอาการปวดข้อ (visual analogue pain score) หลังจาก 3 เดือน ได้ 0 - 1 คะแนน ตรวจสอบกำลัง grip strength ไม่แตกต่างกับมืออีกข้างที่ไม่ได้บาดเจ็บ และแนวกระดูกดีทั้งหมด
- สรุป** : ถึงแม้เป็นการศึกษานำร่อง การผ่าตัดวิธี interdigital dynamic fixator เป็นวิธีที่ประหยัดค่าใช้จ่าย ใช้งานง่าย ให้ผลการรักษาที่ดี ขอแนะนำเป็นหนึ่งในทางเลือกในการรักษากระดูกหักของนิ้วมือส่วนต้นชนิดแตกย่อย (comminuted periarticular base of proximal phalanx fracture)
- คำสำคัญ** : การยึดฝากนิ้วเคียง, กระดูกหักของนิ้วมือส่วนต้นชนิดแตกย่อย.

Fracture of metacarpal and phalangeal bones have been estimated as 20% of upper extremities.⁽¹⁾ Traffic accidents and body assaults are the main causes. Moreover, Phalangeal fracture, especially proximal phalange, was found twice more than metacarpus bone.⁽²⁾

Conservative treatment, by splinting and casting, was sufficient for simple fracture. On the contrary, intraarticular fracture was indicated for surgery. Anatomic alignment, stable fixation and early range of motion are surgical goal. Despite the high volume of patients, there is no appropriate surgical technique for comminuted phalangeal fracture, especially, intraarticular base of P1.^(3, 4) Although many surgeons still prefer stable fixation, for example, plate and screws system. Main disadvantage of poor results from joint stiffness still persist.^(5 - 7)

This study was aimed to invent another alternative surgical technique, adjacent interdigital pinning, for treatment intraarticular base P1. Multiple K-wires were used to maintain phalangeal alignment with adjacent digit. Position of K-wire placement is also important, and will be described later.⁽⁸⁻¹¹⁾ After the operation, patients will be encouraged to take early post-op exercise for prevention of joint stiffness.

Materials and Methods

A total of 3 patients (all male) with periarticular base of P1 fracture were surgically treated at the Department of Orthopedics, Queen Savang Vadhana Memorial Hospital, Sriraja Chonburi, between July 2016 and March 2017. The patients' demographic data are shown in Table 1.

Inclusion criteria included patients who have individual closed periarticular base of P1 fracture of

index, middle and ring finger, with age between 20 – 60 years. Exclusion criteria included all those patients who have multiple injuries or life threatening condition, segmental fracture of the phalange, multiple digits fractures and pathologic fracture. Those who were presented for more than 3 weeks after injury were also excluded.

All patients gave their informed consent before the study. After surgery, their pain was assessed using the visual analog scale (VAS). ROM was determined by goniometry (3 times). Functional hand activities were assessed by Belsky's criteria for assessment of finger injuries.

Patient assessments were done in the preoperative stage, the early postoperative stage, 1st and 3rd month after the operation and grips strength were assessed by hand-held dynamometer compared to uninjured sides at 3rd month.

Plain radiograph was utilized in determination of bone union and were repeated in the postoperative stage after 3 months.

Methods: surgical technique

Under regional or general anesthesia, the patient was in supine position. A periarticular base of P1 fracture was reduced by distal traction (Figure 1). Early joint motion exercise was encouraged because both metacarpophalangeal (MCP) and proximal interphalangeal (PIP) remained free of motion. The first pin was inserted at the neck of P1 of injured digit through the P1 of adjacent digit after reduced by distal traction and PIP in extended position to maintain the traction force. The second pin was inserted at base of P1 through the adjacent digit as diagram 1 - 3 to maintain the reduction. The third pin may be inserted

at the mid-P1 to correct angulation and improved fracture stability. The finger rotation was checked by full flexion of all digits. Fluoroscopy was used to check the alignment and reduction. Exercise then began immediately after the operation. The pins were removed after clinical and radiographic union.

There were several structures at risk for applying K-wire in position. First, lateral bands which were combined with extrinsic extensor tendon and intrinsic muscle of hand through extensor hood. Evading this structure was important step for early motion of phalanx. Harris et al. studied the anatomy

of the extensor mechanism and found that lateral bands would dorsally translate from proximal phalanx in all extension position of MCP, PIP and DIP. Having studied the report, we suggested applying pin while PIP was in fully extended position (Figure 2).

Statistical analysis

Demographic characteristics (age, sex) were documented. The Microsoft Excel tests (mean) were used to analyze in variables affecting the outcome (ROM of pre- and post-intervention, VAS, Belsky's criteria) (Figure 3).

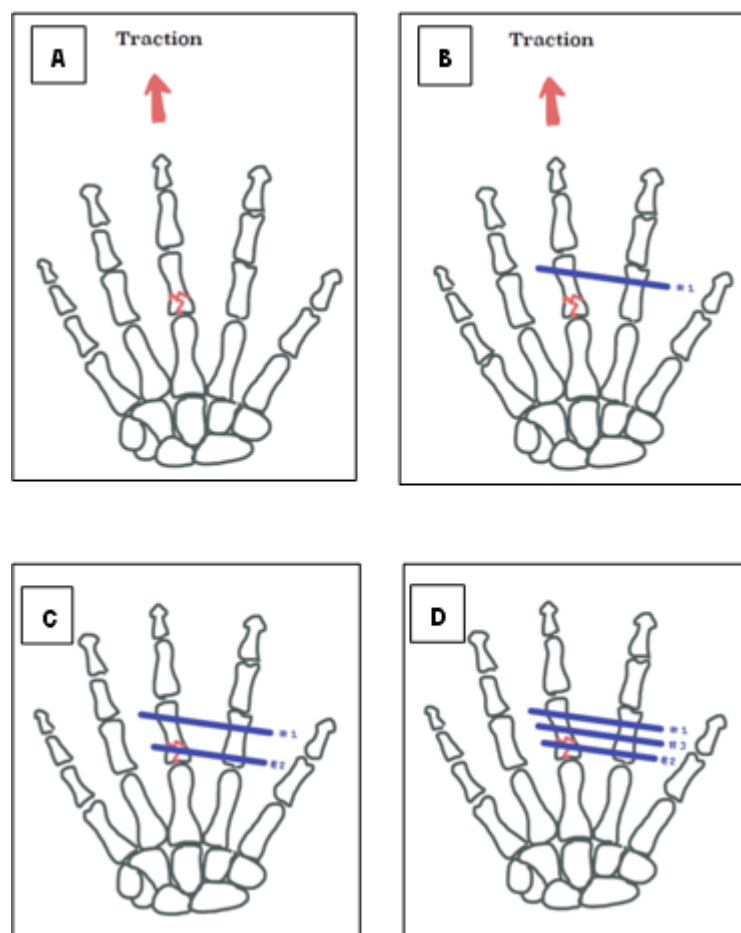


Figure 1. Periarticular base of P1 fracture was reduced by surgical technique in order.

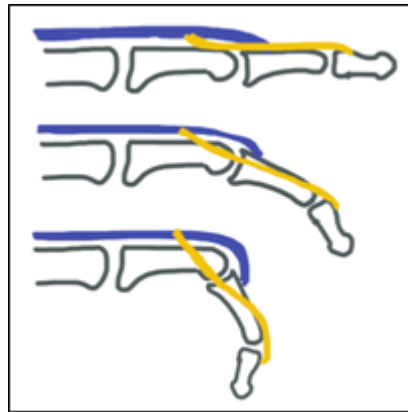


Figure 2. In the extended finger, the point of origin of the lateral bands is shown. In the lower part of the figure, when the finger started to flex, the lateral bands became more volar in relation to PIP joint. ⁽¹⁰⁾

Belsky's Criteria for Assessment of Finger Injuries. Total Active Movement (TAM) Is a Summation of Total Active Flexion Range of the MCP and IP Joints.		
Excellent	Good	Poor
Pain-free union, and No deformity, and TAM > 215 ⁰ , and PIP motion > 100 ⁰	Pain-free union, and Minimal deformity and TAM ≥ 180 ⁰ , and PIP motion ≥ 80 ⁰	Pain or non-union, or Deformity affecting function/cosmesis, or TAM < 180 ⁰ , or PIP motion < 80 ⁰

Figure 3. Belsky's criteria for assessment of finger injuries.

Results

Table 1. Demographic data of patients.

Case	Sex	Age	Cause	finger	Location	Timing to surgery (days)	Operation time (minutes)	Anesthesia
I	M	57	Motorcycle accident	Right middle finger	Intra-articular base & shaft P1	2	45	GA
II	M	22	Motorcycle accident	Right middle finger	Intra-articular base P1	2	45	GA
III	M	25	Motorcycle accident	Right index finger	Intra-articular base P1	0	30	LA

Table 1 : All the three cases were male, aged between 25 to 57 years old. They suffered from traffic motorcycle injuries on their right hands. The locations of fracture were index and middle fingers. We performed operation within 2 days. There was one case that we performed under local anesthesia technique.

Case 1. Thai male, 57-year-old, suffered from right middle finger pain for 5 hours from a motorcycle accident. The diagnosis was closed periarticular fracture of shaft and base P1. Therefore, we used adjacent interdigital pinning technique. (Figure 5)

Case 2 Thai male, 22- years- old, suffered from right middle finger pain for 3 hours from a motorcycle accident. He was diagnosed as closed fracture intra-articular base P1 of middle finger. (Figure 6)

Case 3. Thai male, 25-year-old, came to the hospital with right index pain for 4 hours from a motorcycle accident. He was diagnosed as closed fracture base P1 of right index finger (Figure 7).

Table 2. Results of treatment.

Case	F/U (Weeks)	VAS at 3 months	TAM (degree)	Total PIP ROM Injured digit (Flex, Ext) (degree)	Total PIP ROM Nearby digit (Flex, Ext) (degree)	Grip strength (% compared to uninjured side)	Belsky's criteria (Injured digit)	Complication
I	24	0	240	90 (100, 10)	100 (100,0)	80	Good	-
II	20	1	260	100 (100, 0)	100 (100,0)	90	Excellent	-
III	12	0	210	80 (90, 10)	100 (100,0)	80	Good	-

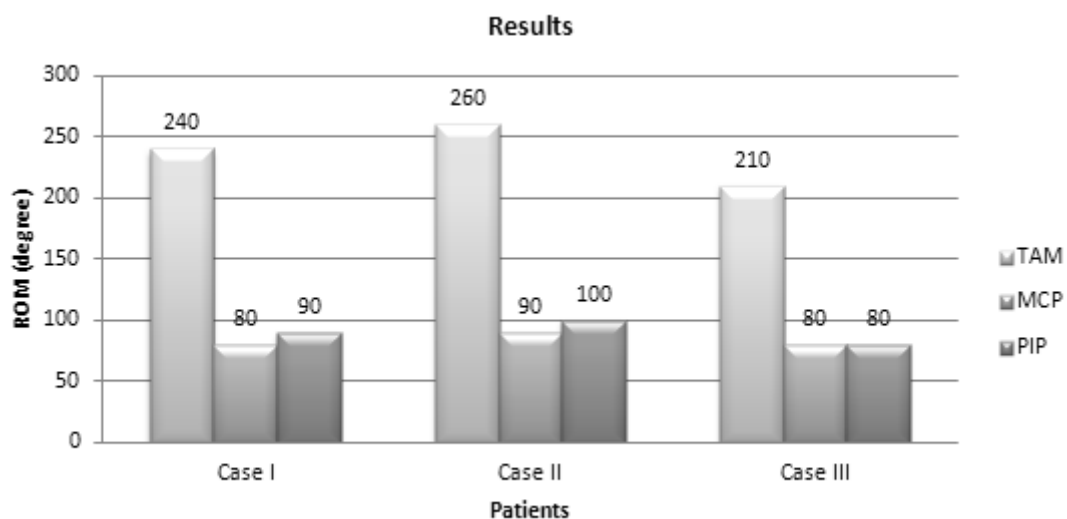


Figure 4. Final ROM of injured fingers.

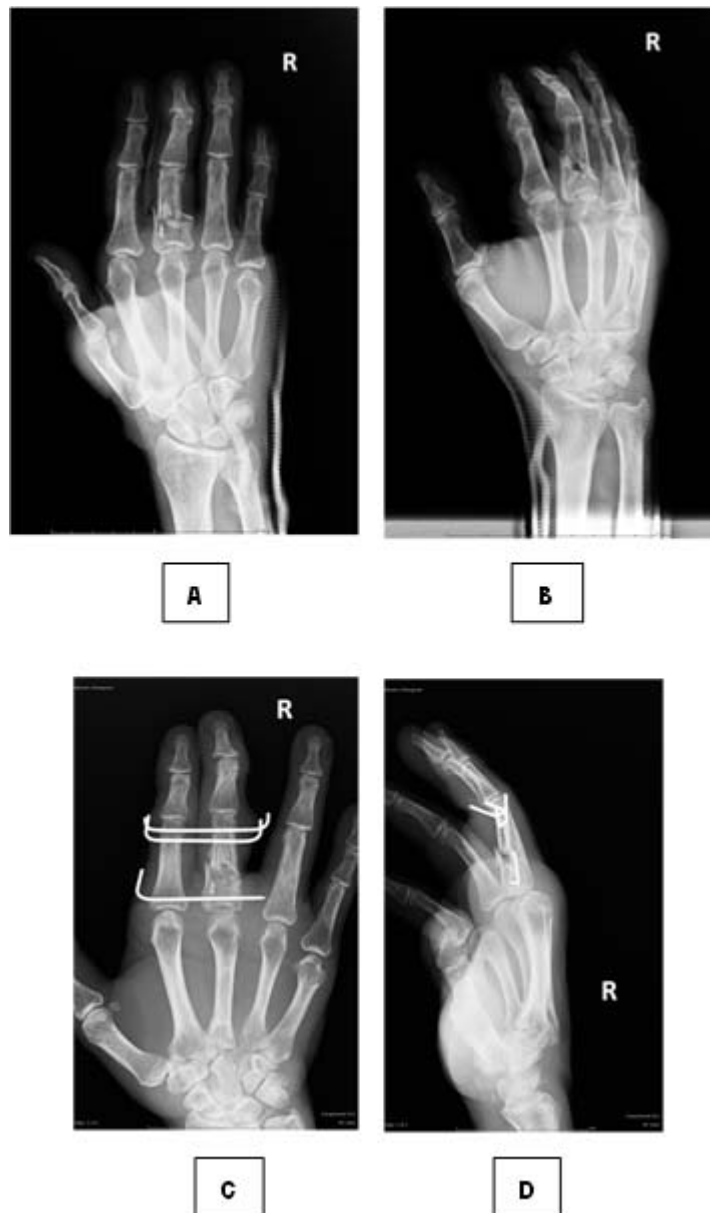

Figure 5. Before operation (A) anteroposterior view (B) oblique view, After operation (C) anteroposterior view (D) lateral view.

Our study, adjacent interdigital pinning, showed the results after follow up at minimal 12 weeks. (Table 2) Even intra-articular or periarticular base P1 fracture cases, our technique revealed better ROM of MCP and PIP at minimum 80 degrees and more than 210 degrees of total active ROM. In term of

Belsky's criteria (Figure 2), our patients were classified as good and excellent results (Figure 4). All patients could return to previous occupation with no deficit function and the ROM of all adjacent digits regained their full motion after applying the pins.

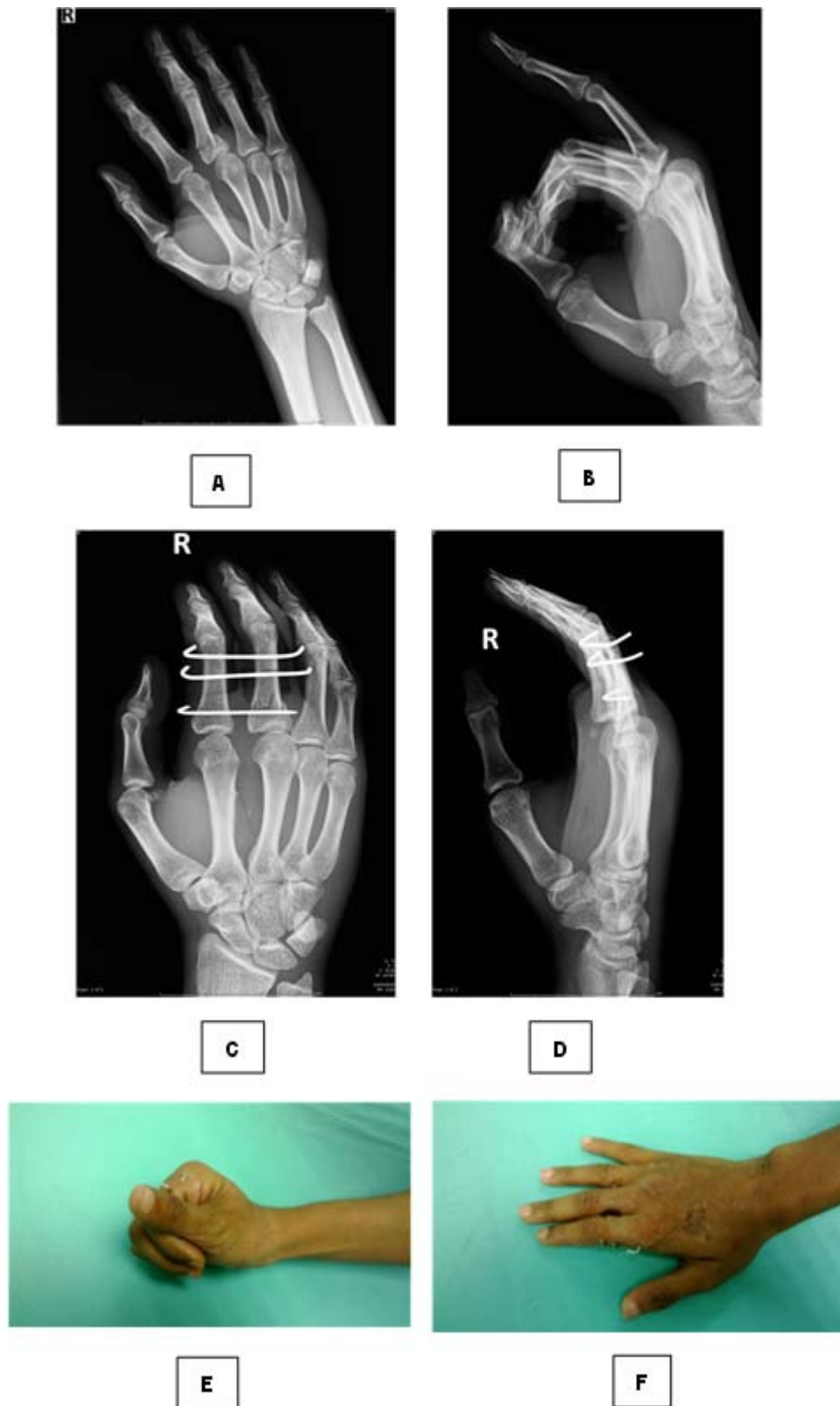


Figure 6. Before operation (A) anteroposterior view (B) lateral view, After operation (C) anteroposterior view (D) lateral view, begin range of motion exercise after operation. (E) full flexion (F) full extension.

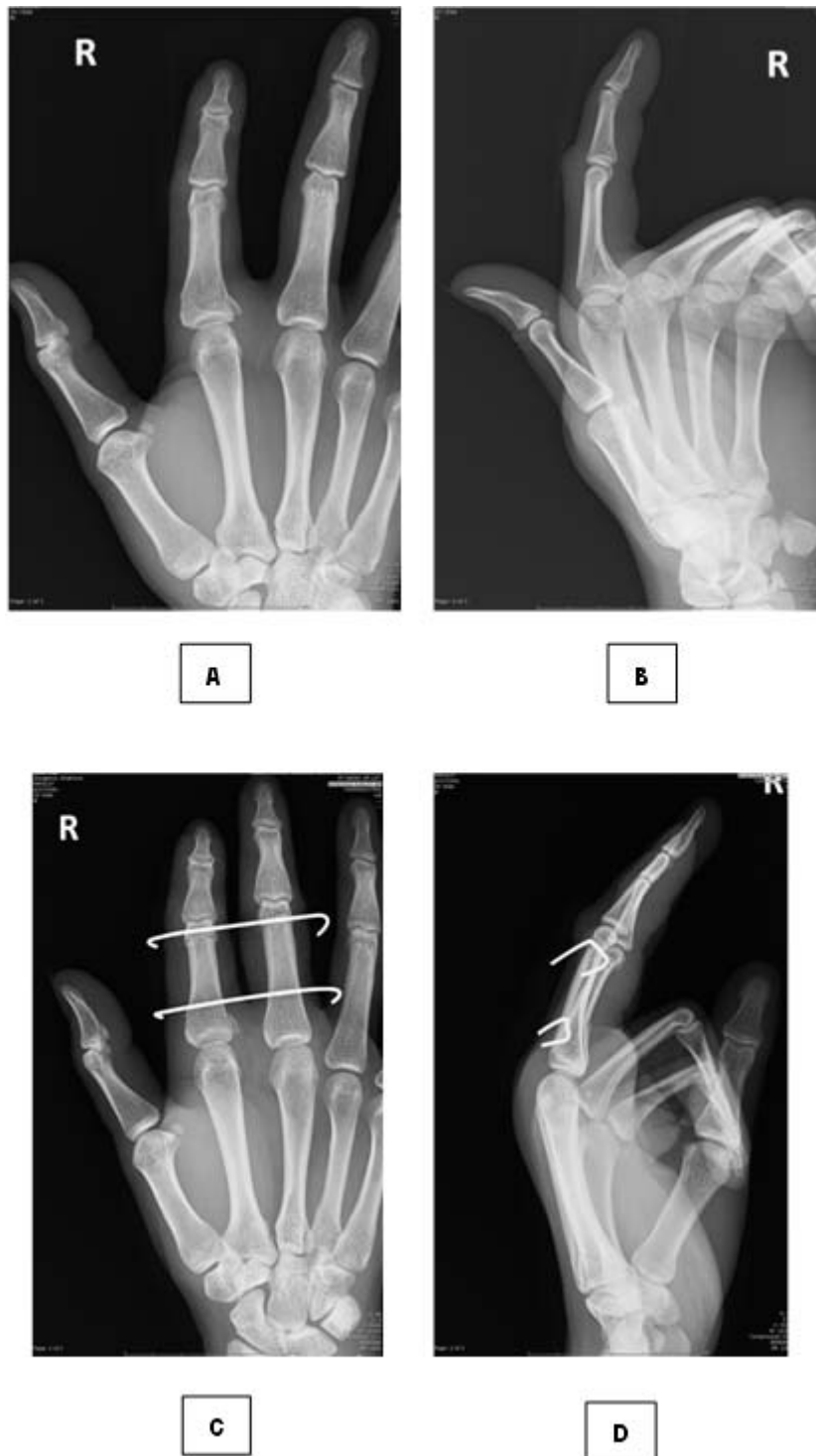

Figure 7. Before operation (A) anteroposterior view (B) oblique view, after operation (A) anteroposterior view (B) lateral view.

Discussion

There are many methods of treatment of periarticular base phalangeal fracture but the results are still mediocre. K-wire fixation has several disadvantages, loss reduction and less stability require post operative immobilization. On the other hand, screw-and-plate fixation would be more injury to soft tissue, leading to scar adhesion and loss of motion. Gonzalez MH, et al. ⁽⁶⁾ showed the results of screw-and-plate surgery, revealed mean ROM of PIP after surgery is 66 degree. Especially intra-articular fracture would deteriorate the ROM, total active motion (TAM) 169 degree, compared to extra-articular fracture TAM which was 213 degree. ⁽⁶⁾ Tan V, et al. ⁽⁷⁾ showed poor results of intra-articular phalangeal fracture after surgery described by Belsky's criteria.

The advantages of our technique are closed reduction of fractures, low cost, easy and can be applied to comminuted fracture of the P1 base and shaft fracture. The disadvantages are limited to the index, middle and ring fingers and cannot be applied to multiple digit fractures.

Compared to Gonzalez MH, et al. our techniques showed superior results in PIP motion (80 degree), TAM (210 degree) and good functional results due to Belsky's criteria.

Due to Hargreaves DG, et al. ⁽¹²⁾, reported percutaneous tract infection rate was 34% in 6 weeks (10 of 29 pins). In our series, there was no infection, non-union and no complication to adjacent digit. Despite our favorable results, recruiting more patients was our purposed and new design of framework for multiple phalangeal fractures.

Our limitation was few cases of patients and that should be recruited more in the future studies.

Conclusion

Adjacent interdigital pinning is economical, easy for application and provides good results, on the one hand. On the other hand, this technique is only applicable for single digit injury of index, middle and ring finger. Thumb and little finger are not suitable due to different arc of motion.

Adjacent interdigital pinning is an effective technique and should serve as an alternative way to manage periarticular P1 fracture.

References

1. สำนักนโยบายและยุทธศาสตร์ สำนักงานปลัดกระทรวงสาธารณสุข. สถิติสาธารณสุข พ.ศ. 2557. นนทบุรี:สำนักนโยบายและยุทธศาสตร์; 2558.
2. Van Onselen EB, Karim RB, Hage JJ, Ritt MJ. Prevalence and distribution of hand fractures. *J Hand Surg Br* 2003;28:491-5.
3. Henry MH. Fractures of the proximal phalanx and metacarpals in the hands: Preferred methods of stabilization. *J Am Acad Orthop Surg* 2008;16:586-95.
4. Curtin CM, Chung KC. Use of eight-hole titanium miniplates for unstable phalangeal fractures. *Ann Plast Surg* 2002;49:580-6.
5. Ip WY, Ng KH, Chow SP. A prospective study of 924 digital fractures of the hand. *Injury* 1996; 27:279-85.
6. Gonzalez MH, Hall M, Hall RF Jr. Low-velocity gunshot wounds of the proximal phalanx: Treatment by early stable fixation. *J Hand Surg Am* 1998;23:150-5.
7. Tan V, Beredjikian PK, Weiland AJ. Intra-articular fractures of the hand: treatment by open reduction and internal fixation. *J Orthop*

- Trauma 2005;19:518-23.
8. Vargas A, Chiapas-Gasca K, Hernández-Díaz C, Canoso JJ, Saavedra MÁ, Navarro-Zarza JE, et al. Clinical anatomy of the hand. *Rheumatol Clin* 2012;8:25-32.
 9. Schweitzer TP, Rayan GM. The terminal tendon of the digital extensor mechanism: Part I, anatomic study. *J Hand Surg Br* 2004;29:898-902.
 10. Harris C, Rutledge GL Jr. The functional anatomy of the extensor mechanism of the finger. *J Bone Joint Surg Am* 1972;54:713-26.
 11. Lu WW, Furumachi K, Ip WY, Chow SP. Fixation for comminuted phalangeal fractures. A biomechanical study of five methods. *J Hand Surg Br* 1996;21:6:765-7.
 12. Hargreaves DG, Drew SJ, Eckersley R. Kirschner wire pin tract infection rates: a randomized controlled trial between percutaneous and buried wires. *J Hand Surg Br* 2004;29:374-6.